ANIFS, Augsburg 2020

Herzkatheterinterventionen im Neugeborenen- und Säuglingsalter

Heutige Möglichkeiten und Perspektiven für morgen

P. Ewert
Deutsches Herzzentrum München

Katheterinterventionen

A. Grüntzig

1. Koronarangioplastie
1977 in Zürich

Ballonatrioseptostomie nach Rashkind

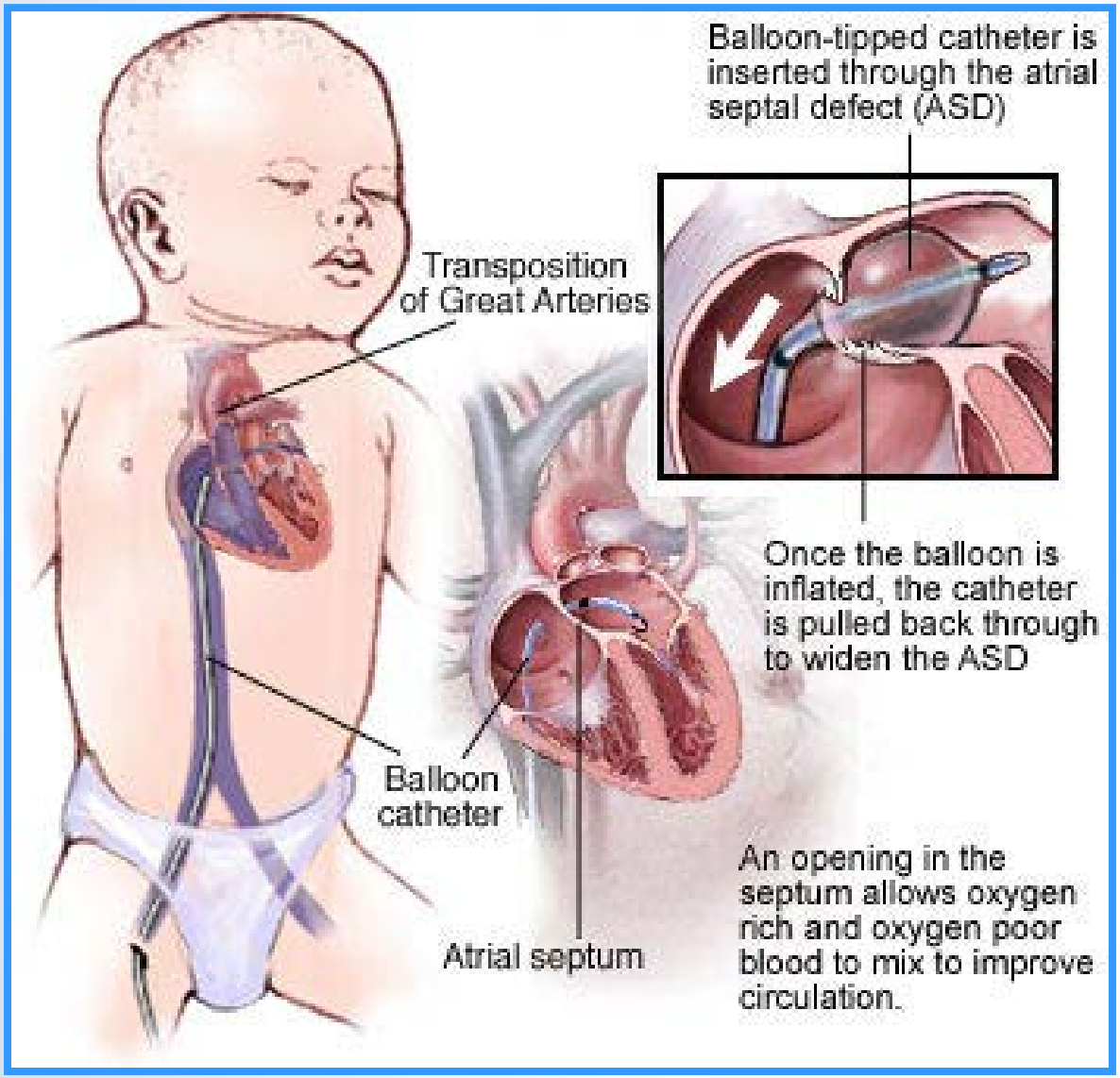

W.J. Rashkind

Ballonatrioseptostomie nach Rashkind

Circulation
JOURNAL OF THE AMERICAN HEART ASSOCIATION

American Heart Association®

Transposition of the Great Arteries: Results of Palliation by Balloon Atrioseptostomy in Thirty-one Infants

WILLIAM J. RASHKIND and WILLIAM W. MILLER

Circulation. 1968;38:453-462

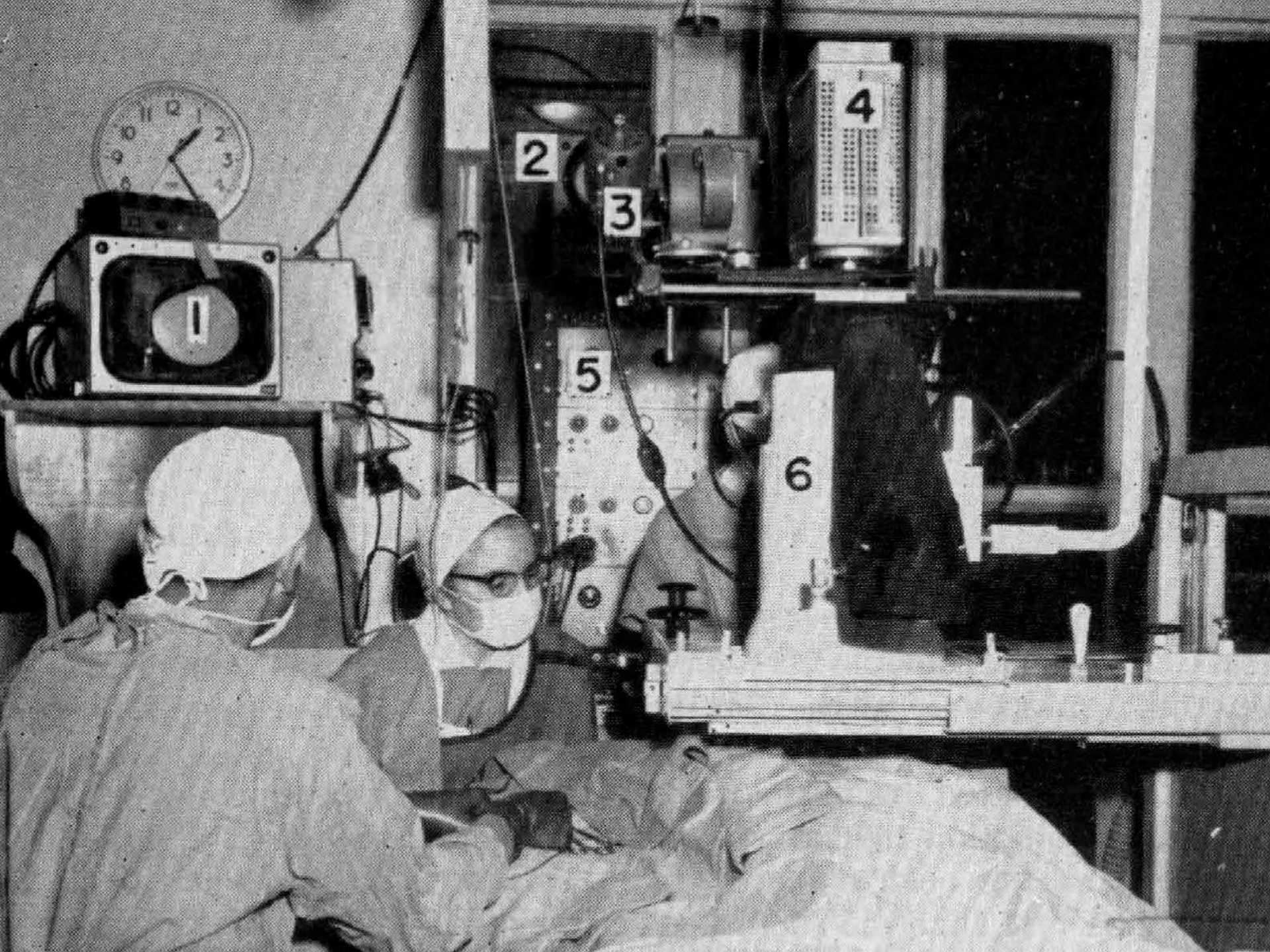
1
2
3
4
5
6

Ballonatrioseptostomie nach Rashkind unter alleiniger Ultraschallkontrolle

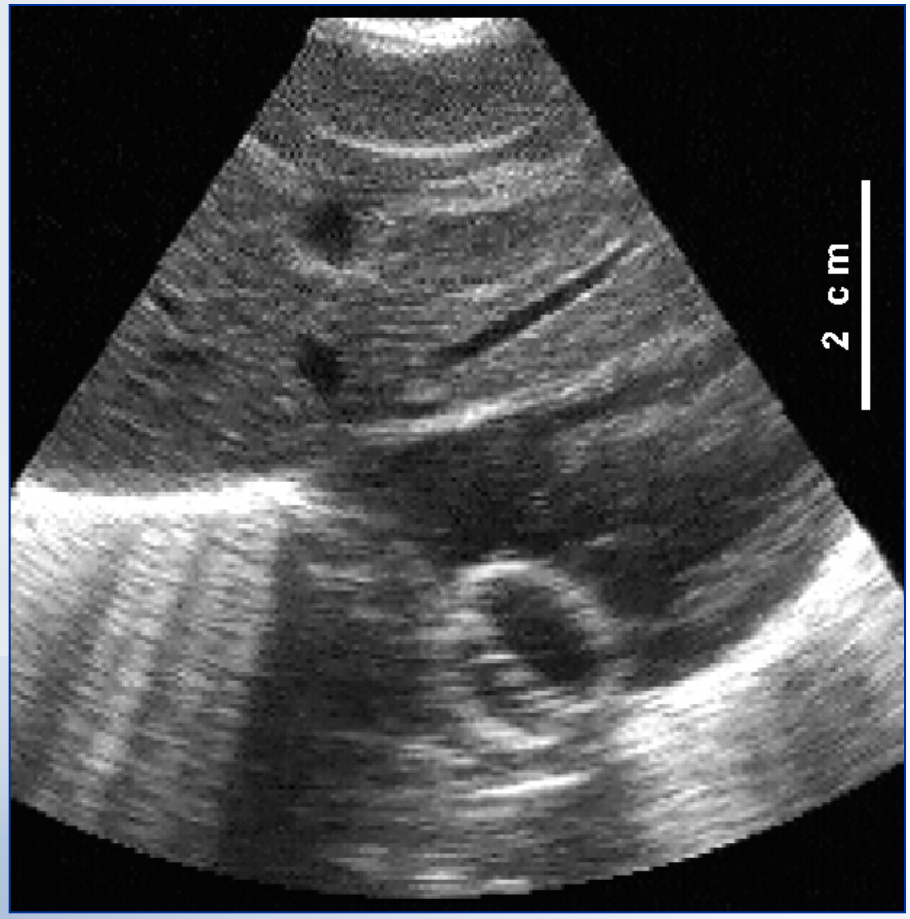

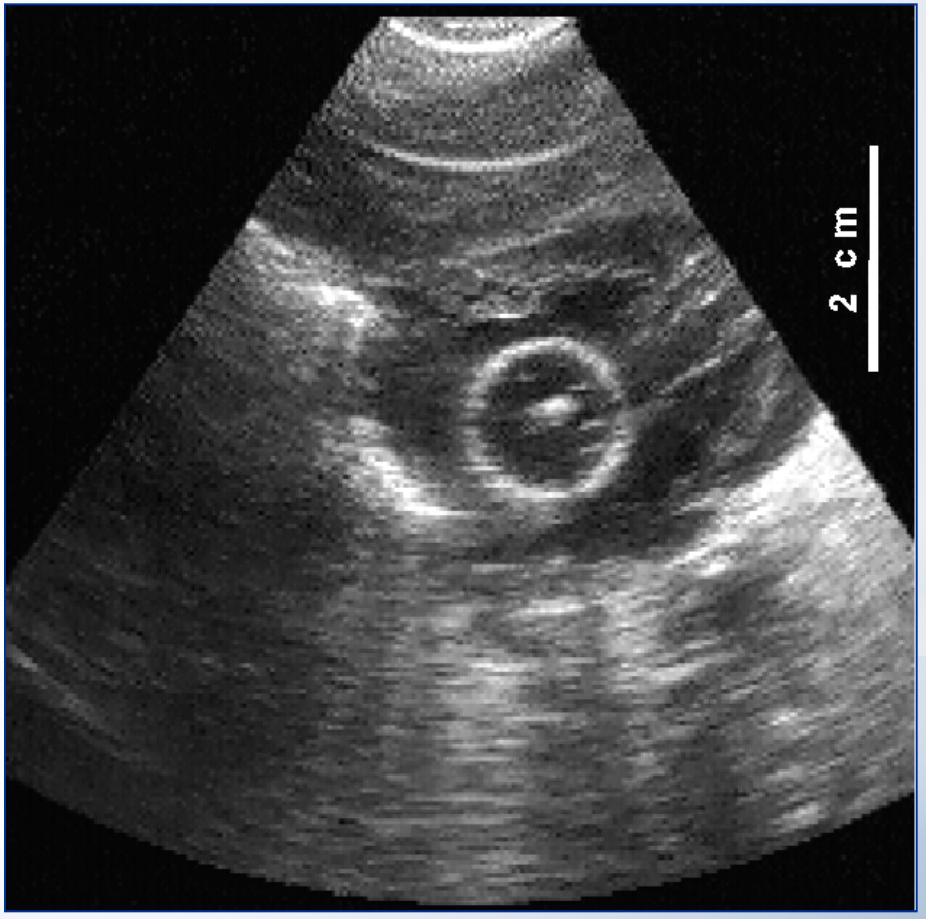

Neugeborene mit univentrikulärem Herz

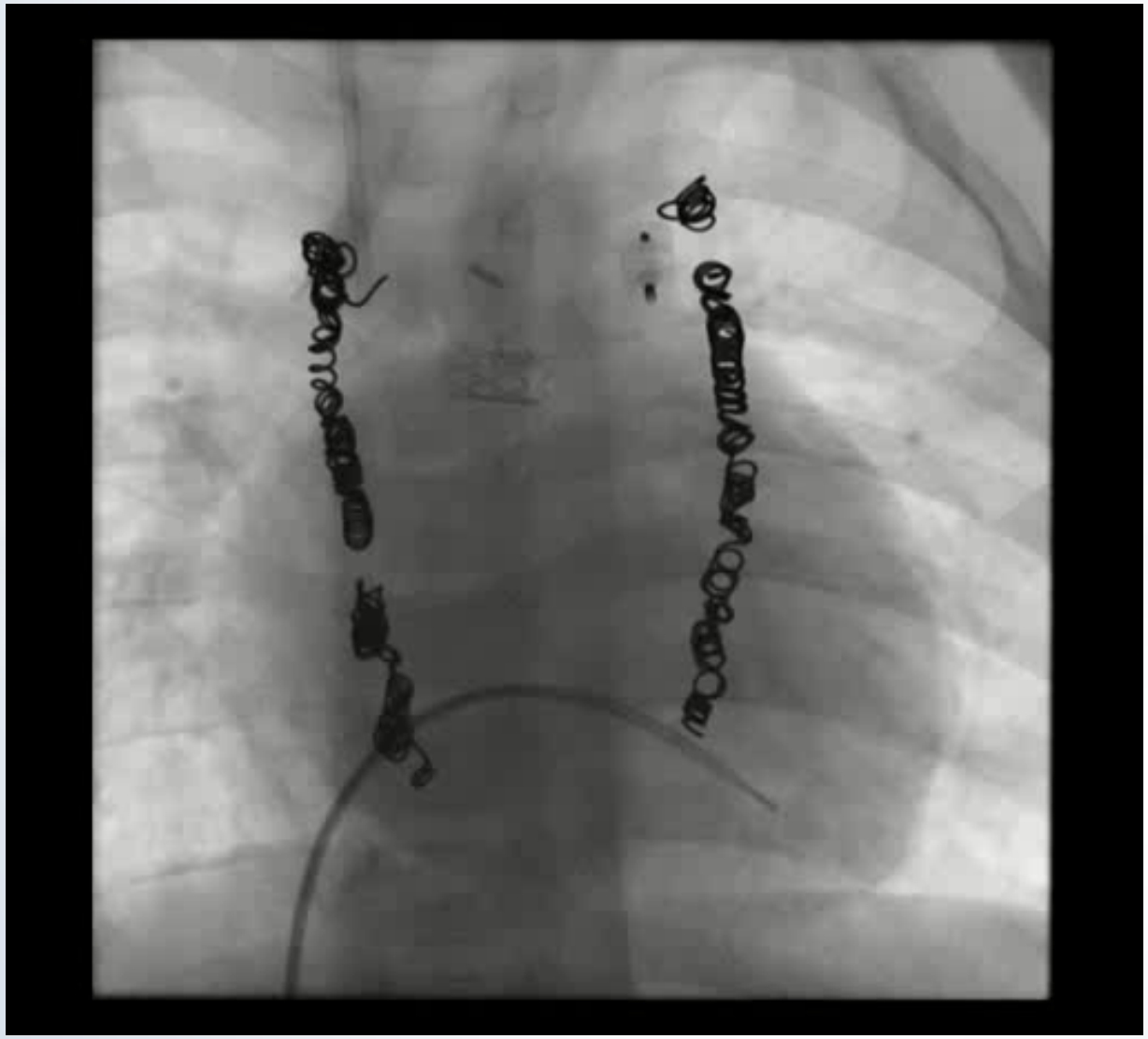

...aller Anfang ist schwer.

Neugeborene mit univentrikulärem Herz

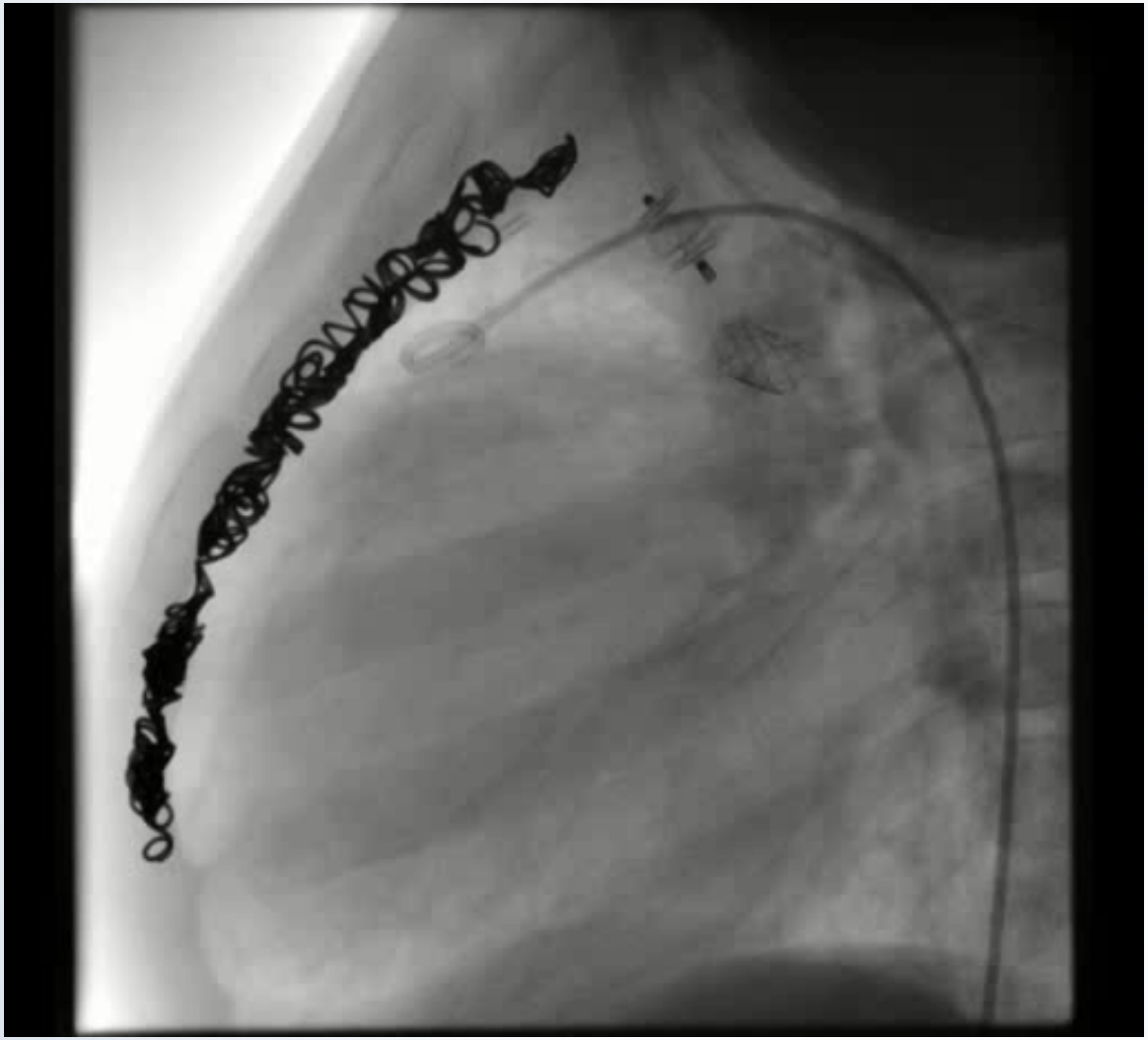

...aller Anfang ist schwer.

Neugeborene mit univentrikulärem Herz

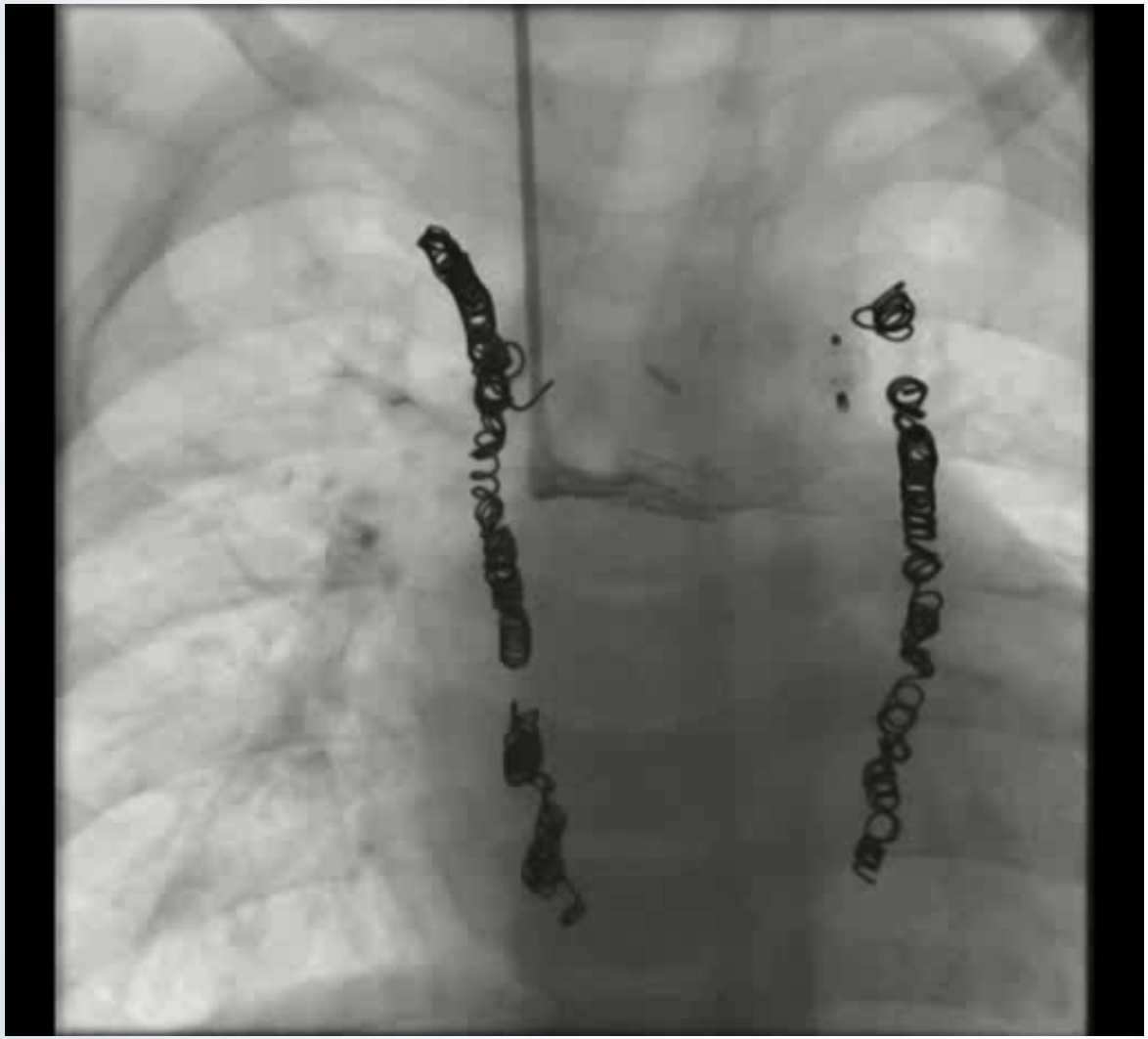

...aller Anfang ist schwer.

Neugeborene mit univentrikulärem Herz

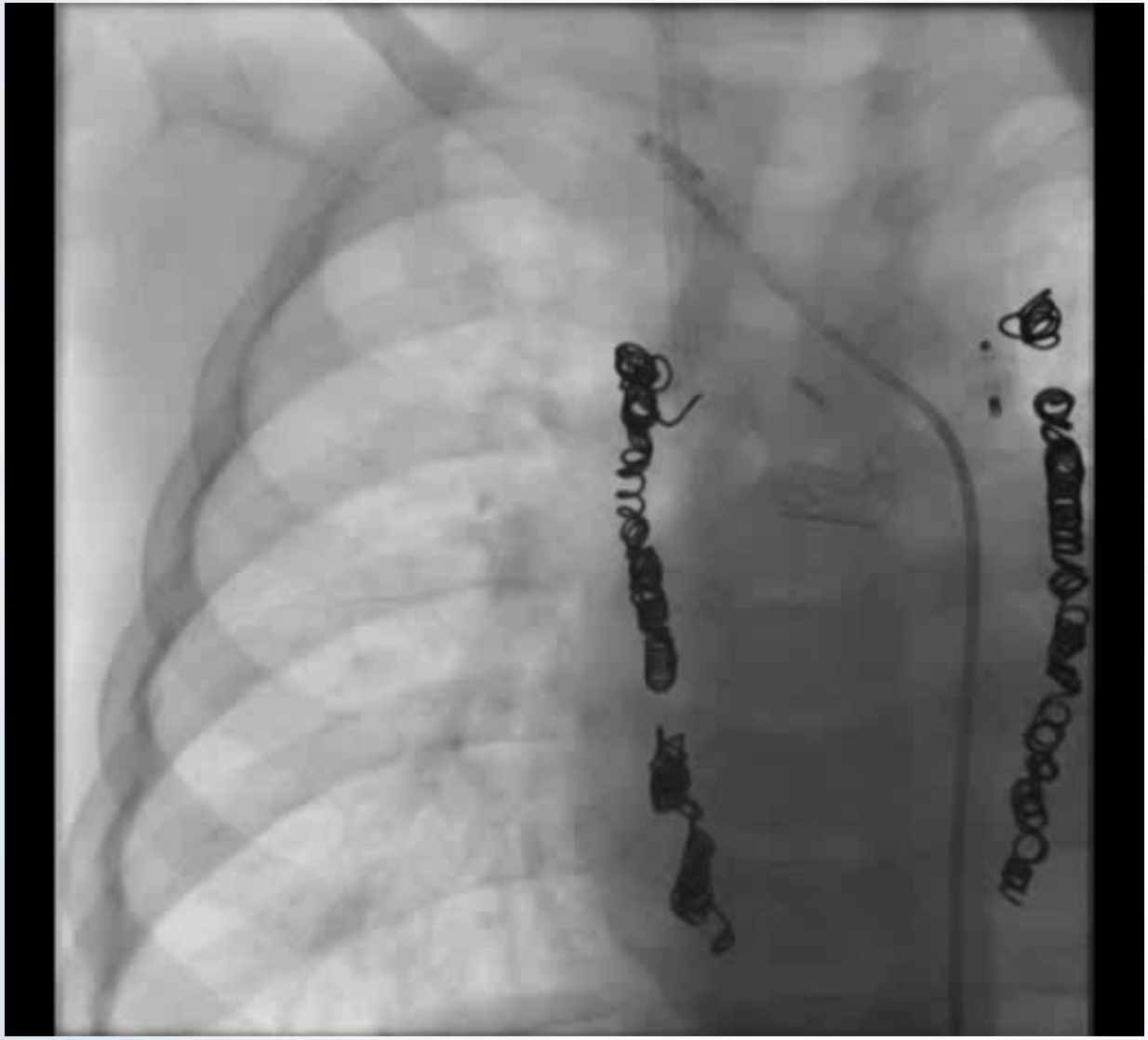

...aller Anfang ist schwer.

ANIFS, Augsburg 2020

Ballondilatation der Aortenstenose



Aortic Valvuloplasty in Pediatric Patients Substantially Postpones the Need for Aortic Valve Surgery

A Single-Center Experience of 188 Patients After up to 17.5 Years of Follow-Up

Sohrab Fratz, MD; Hans Peter Gildein, MD; Gunter Balling, MD; Walter Sebening, MD; Thomas Genz, MD; Andreas Eicken, MD; John Hess, MD

Background—Aortic valvuloplasty (AoVP) is an established procedure regarded as a valid alternative for surgical management of congenital aortic valve stenosis. However, its long-term efficacy in preventing or postponing aortic valve surgery remains uncertain for the i[illegible]im of this study was to study the long-term results of AoVP in pediatric patie[illegible]g aortic valve surgery.

Methods and Results—We reviewe[illegible] patients who received AoVP at the Deutsches Herzzentrum München. [illegible]n of age (group <1 month; n=68) and those ≥1 month of age (group ≥1 mo[illegible] After the first and second AoVP, moderate and severe aortic regurgitation developed in 29% and 14%, respectively, of the patients in group <1 month and in 19% and 29%, respectively, of the patients in group ≥1 month. Survival after 10 years free from aortic valve surgery was 59% (95% confidence interval, 45 to 73) in group <1 month and 70% (95% confidence interval, 59 to 81) in group ≥1 month.

Conclusions—This study shows that the long-term results of AoVP of congenital aortic valve stenosis in pediatric patients and its efficacy in preventing or postponing aortic valve surgery are very good. About two thirds of the patients are free from aortic valve surgery 10 years after AoVP. (*Circulation*. 2008;117:1201-1206.)

…two thirds of the pts.
are free from surgery
10 yrs. After AoVP

Key Words: aortic valve stenosis ■ balloon ■ catheterization ■ pediatrics ■ valvuloplasty

Contents lists available at ScienceDirect

International Journal of Cardiology

journal homepage: www.elsevier.com/locate/ijcard

Balloon valvuloplasty in the treatment of congenital aortic valve stenosis — A retrospective multicenter survey of more than 1000 patients

P. Ewert [a,*], H. Bertram [b], J. Breuer [c], I. Dähnert [d], S. Dittrich [e], A. Eicken [f], M. Emmel [g], G. Fischer [h], R. Gitter [i], M. Gorenflo [j], N. Haas [k], E. Kitzmüller [l], A. Koch [m], O. Kretschmar [n], A. Lindinger [o], I. Michel-Behnke [p], J.H. Nuernberg [q], M. Peuster [k], K. Walter [r], P. Zartner [s], F. Uhlemann [t]

[a] Deutsches Herzzentrum Berlin, Germany
[b] Medizinische Hochschule Hannover, Germany
[c] Universitätsklinik Bonn, Germany
[d] Herzzentrum Leipzig, Germany
[e] Universitätsklinik Freiburg, Germany
[f] Deutsches Herzzentrum München, Germany
[g] Universitätsklinik Köln, Germany
[h] Universitätsklinik Kiel, Germany
[i] Landes-Kinderklinik Linz, Germany
[j] Universitätsklinik Heidelberg, Germany
[k] Herz- und Diabeteszentrum Nordrhein-Westfalen, Germany
[l] Universitätsklinik Wien, Austria
[m] Universitätsklinik Erlangen, Germany
[n] Kinderspital Zürich, Switzerland
[o] Universitätsklinik Homburg, Germany
[p] Universitätsklinik Giessen, Germany
[q] Klinikum Links der Weser, Bremen, Germany
[r] Herzzentrum Duisburg, Germany
[s] Deutsches Kinderherzzentrum St. Augustin, Germany
[t] Olgahospital Stuttgart, Germany

20 Zentren
retrospektiv
nicht standardisiert

Contents lists available at ScienceDirect

International Journal of Cardiology

journal homepage: www.elsevier.com/locate/ijcard

Balloon valvuloplasty in the treatment of congenital aortic valve stenosi retrospective multicenter survey of more than 1000 patients

P. Ewert [a,*], H. Bertram [b], J. Breuer [c], I. Dähnert [d], S. Dittrich [e], A. Eicken [f], M. Emmel [g], G. Fisch M. Gorenflo [j], N. Haas [k], E. Kitzmüller [l], A. Koch [m], O. Kretschmar [n], A. Lindinger [o], I. Michel-E J.H. Nuernberg [q], M. Peuster [k], K. Walter [r], P. Zartner [s], F. Uhlemann [t]

[a] Deutsches Herzzentrum Berlin, Germany
[b] Medizinische Hochschule Hannover, Germany
[c] Universitätsklinik Bonn, Germany
[d] Herzzentrum Leipzig, Germany
[e] Universitätsklinik Freiburg, Germany
[f] Deutsches Herzzentrum München, Germany
[g] Universitätsklinik Köln, Germany
[h] Universitätsklinik Kiel, Germany
[i] Landes-Kinderklinik Linz, Germany
[j] Universitätsklinik Heidelberg, Germany
[k] Herz- und Diabeteszentrum Nordrhein-Westfalen, Germany
[l] Universitätsklinik Wien, Austria
[m] Universitätsklinik Erlangen, Germany
[n] Kinderspital Zürich, Switzerland
[o] Universitätsklinik Homburg, Germany
[p] Universitätsklinik Giessen, Germany
[q] Klinikum Links der Weser, Bremen, Germany
[r] Herzzentrum Duisburg, Germany
[s] Deutsches Kinderherzzentrum St. Augustin, Germany

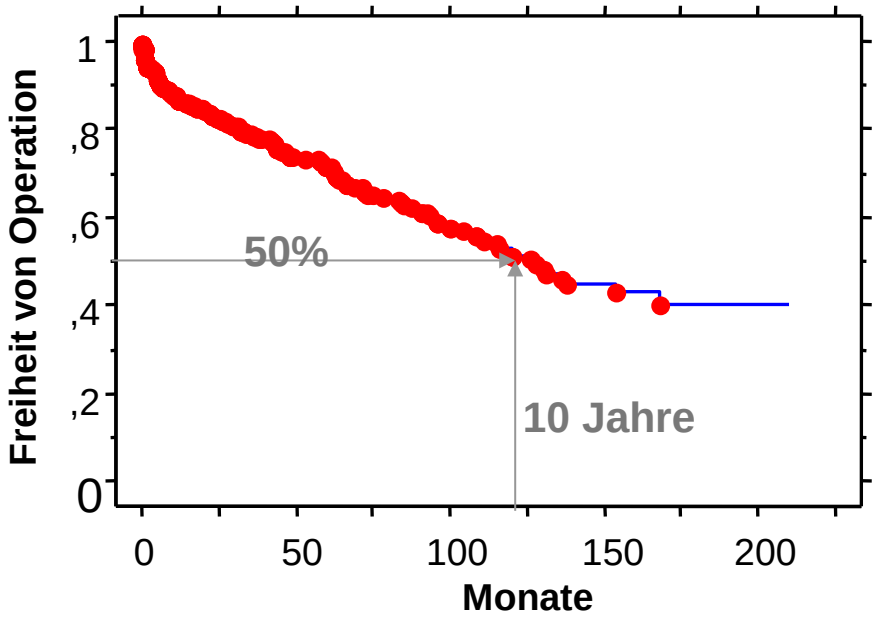

ANIFS, Augsburg 2020

Ballondilatation der Aortenklappe

ANIFS, Augsburg 2020

Ballondilatation der Aortenklappe

Ballondilatation der Aortenklappe

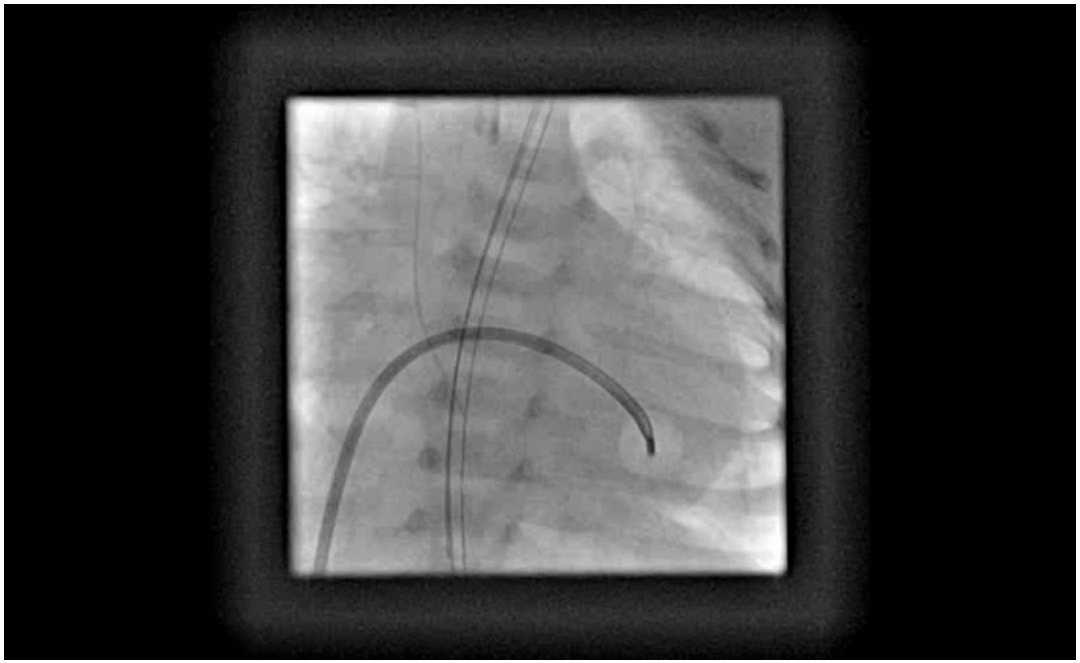

Ballondilatation der Aortenklappe

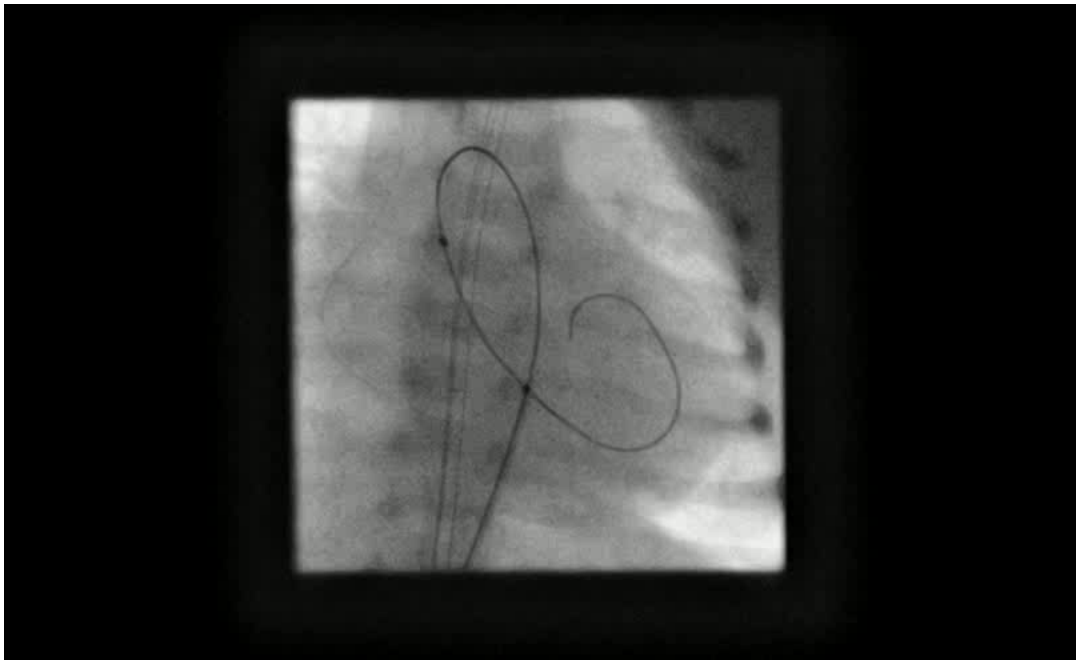

ANIFS, Augsburg 2020

Ballondilatation der Aortenklappe

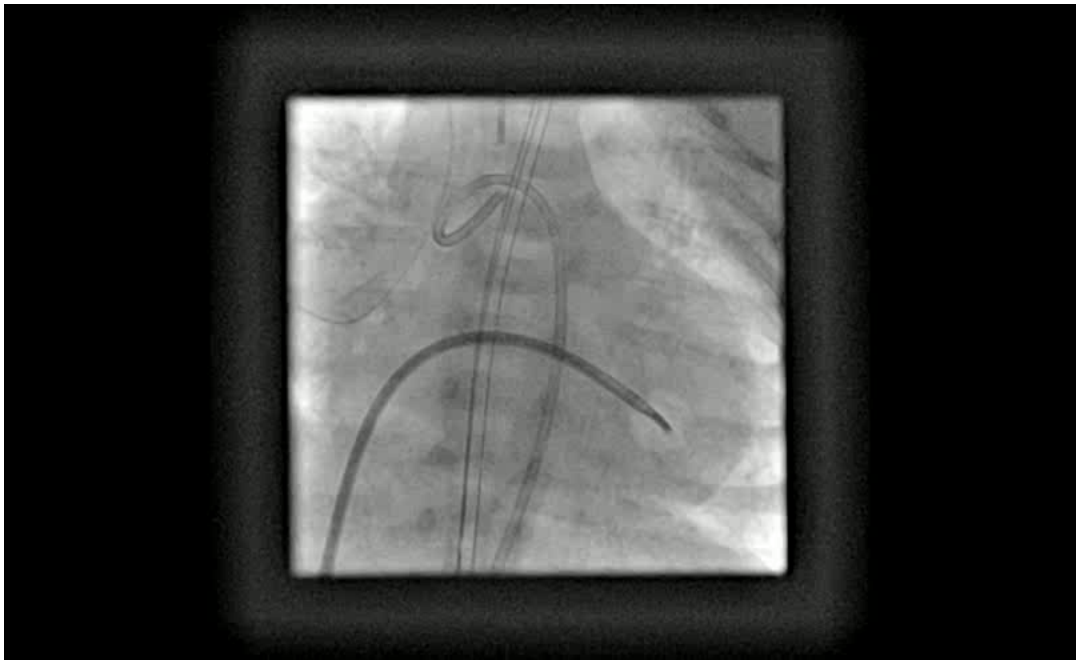

ANIFS, Augsburg 2020

Ballondilatation der Aortenklappe

ANIFS, Augsburg 2020

Ballondilatation der Aortenklappe

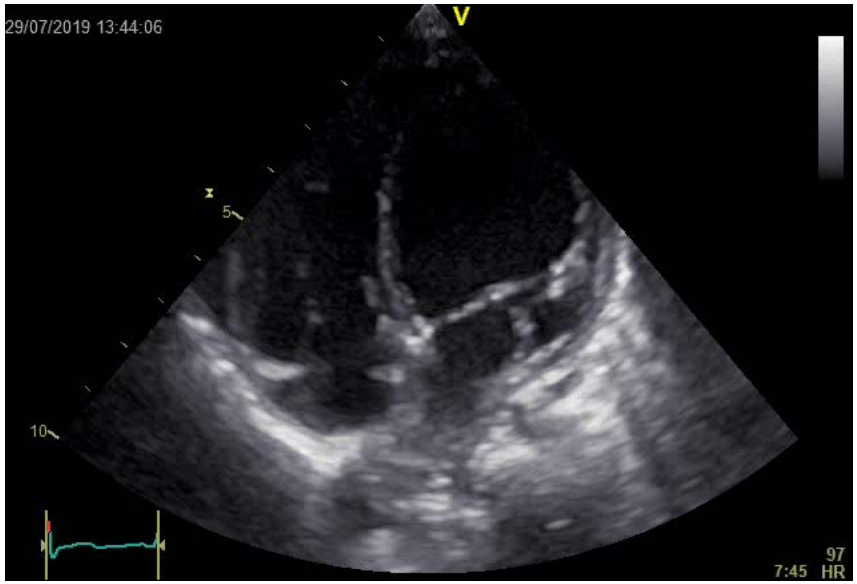

Katheterintervention der Aortenisthmusstenose

Technisch möglich?

art. Schleuse?

Ballon?

Stent?

Katheterintervention der Aortenisthmusstenose

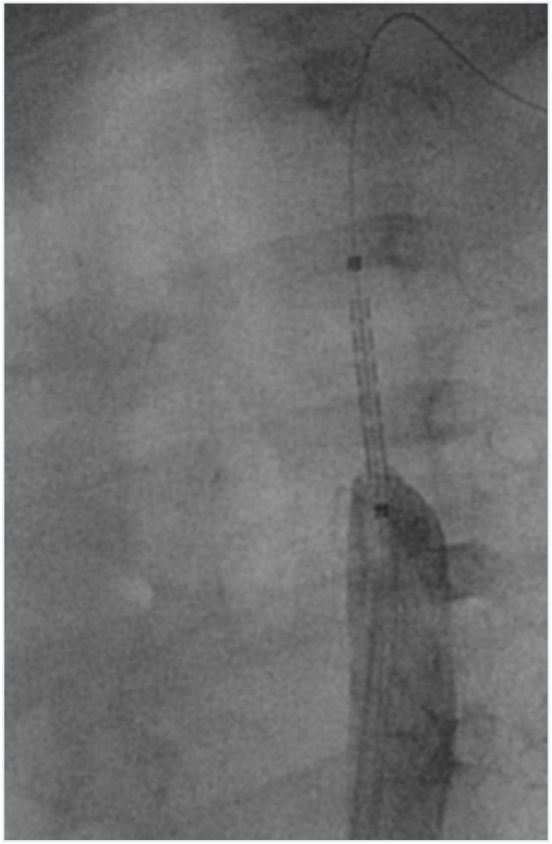

Pt. 4.0 kg, 5F Schleuse, Ballon 5.6mm

Katheterintervention der Aortenisthmusstenose

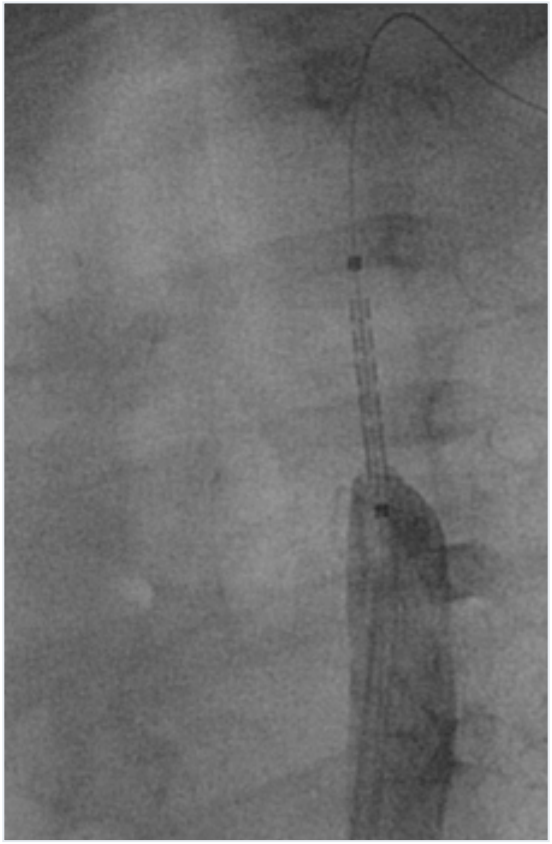

Pt. 4.0 kg, 5F Schleuse, Ballon 5.6mm

ANIFS, Augsburg 2020

Katheterintervention der Aortenisthmusstenose

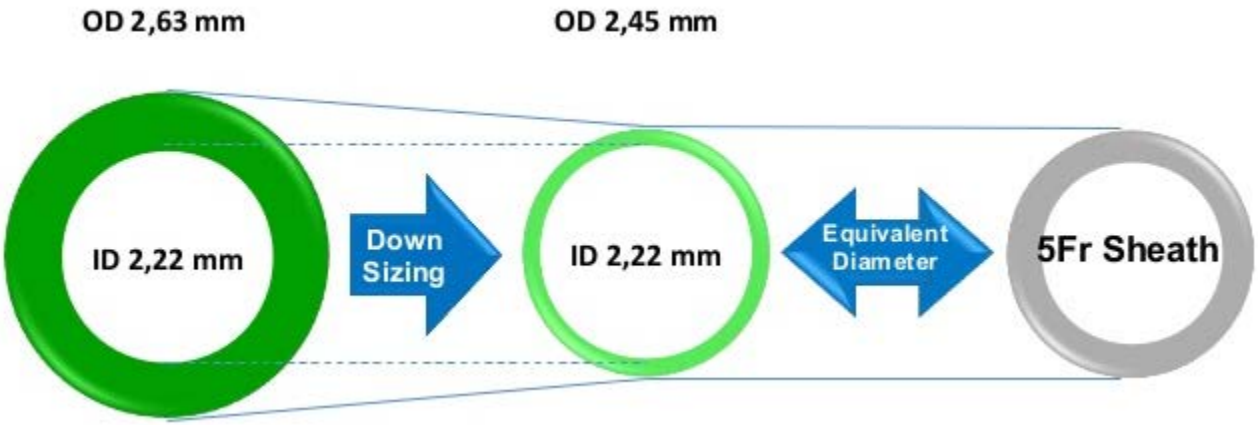

Das „Glide Sheath Slender“-Konzept

Katheterintervention der Aortenisthmusstenose



6 mm



15 mm Ballon

Wie oft muß nachdilatiert werden??

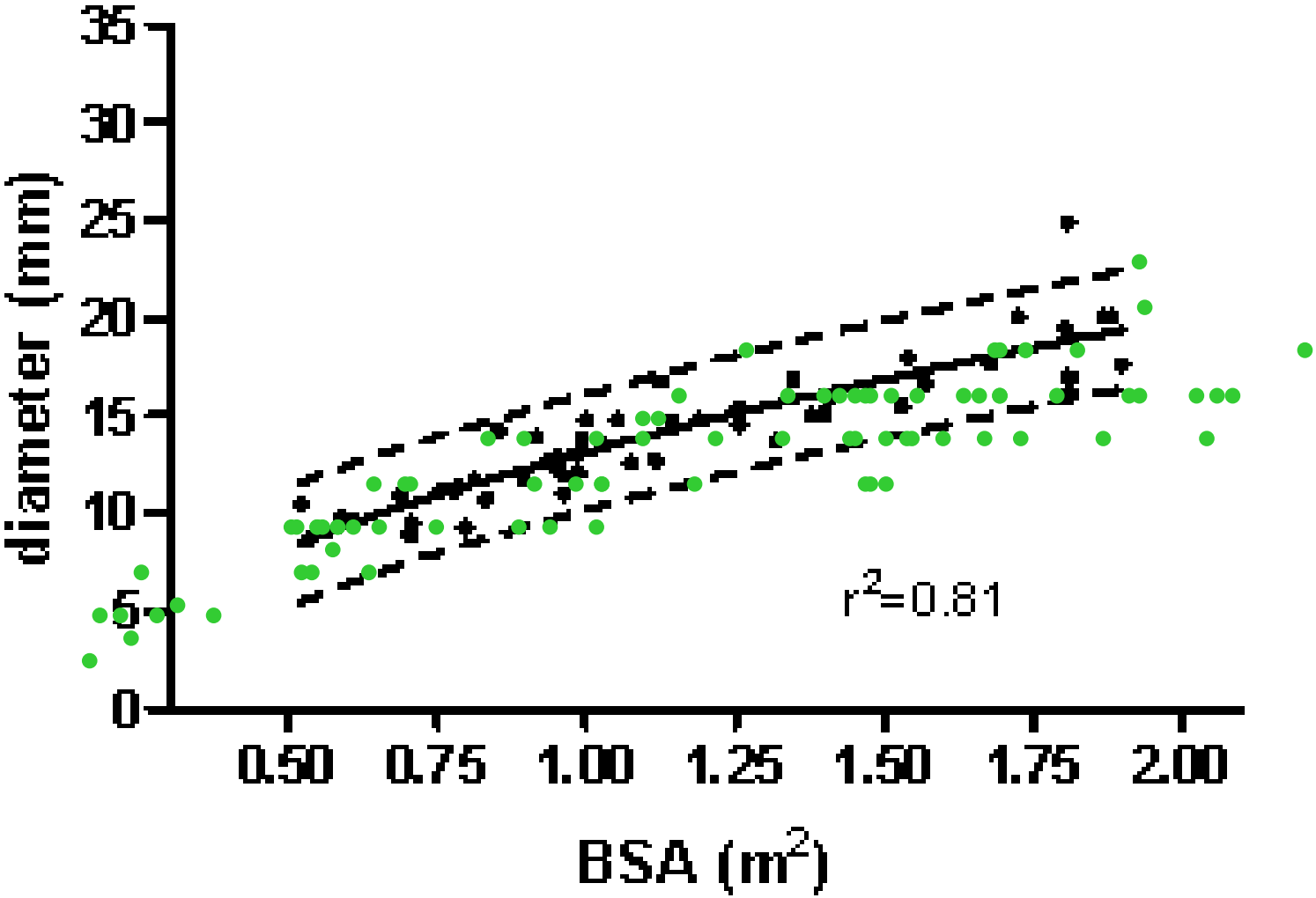

Wie oft muß nachdilatiert werden??

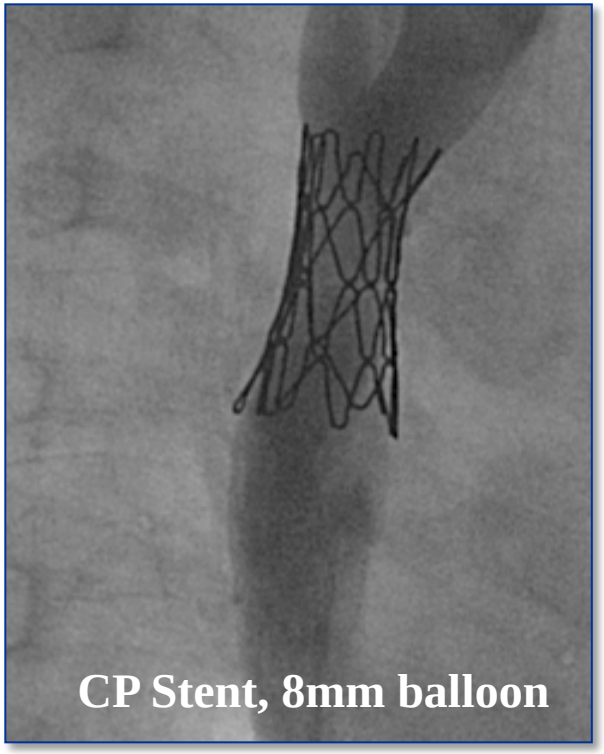

Pat. 3 Jahre, 14kg

Infant	6-8mm
toddler/pre-school	8-10mm
school child	10-12mm
adolescent	14-16mm
adult	18-22mm

goal: gradient always <20mmHg

Katheterintervention der Aortenisthmusstenose

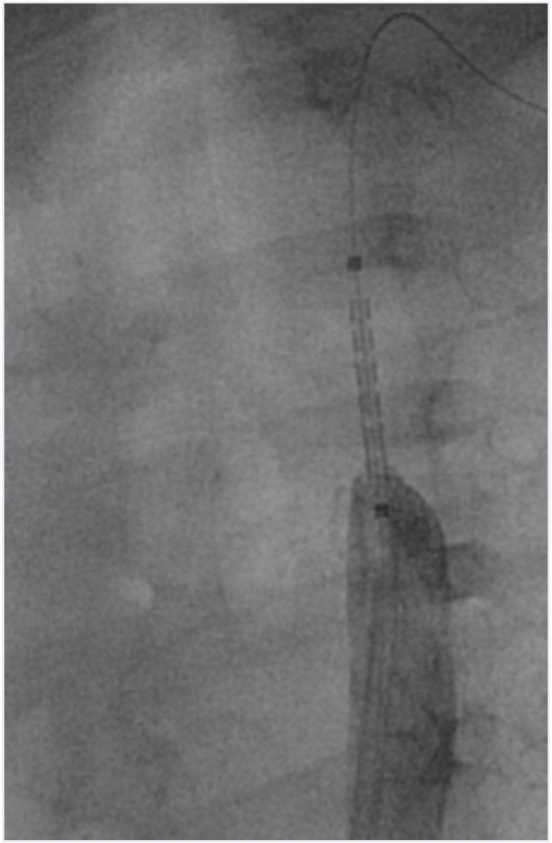

Pt. 4.0 kg, 5F Schleuse, Ballon 5.6mm

Ballondilatation der Pulmonalklappenstenose

Rumbo, 1980 (Kan et al.)

Ballondilatation der Pulmonalklappe

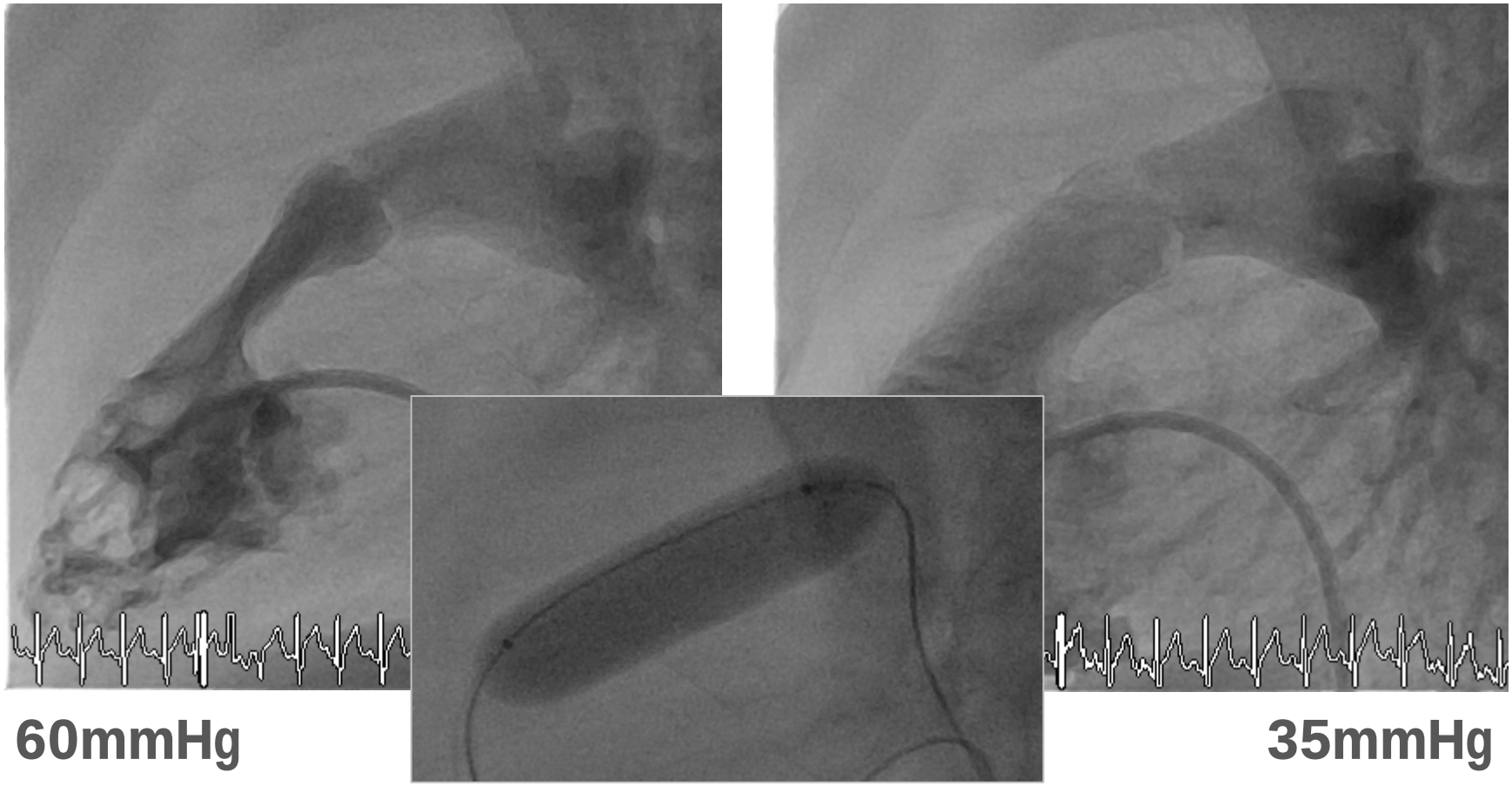

60mmHg

35mmHg

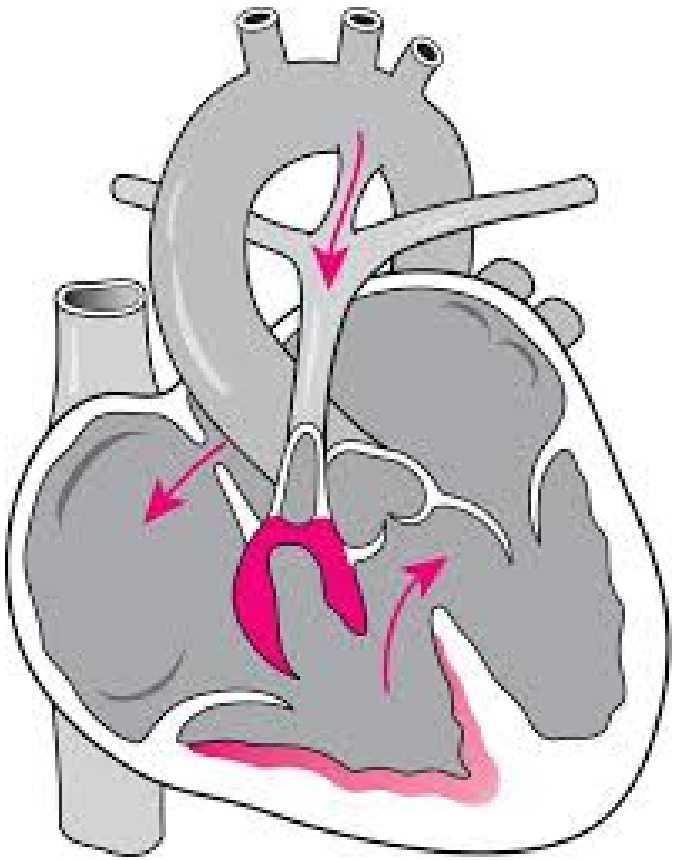

Pulmonalatresie mit VSD

Pulmonalatresie mit VSD

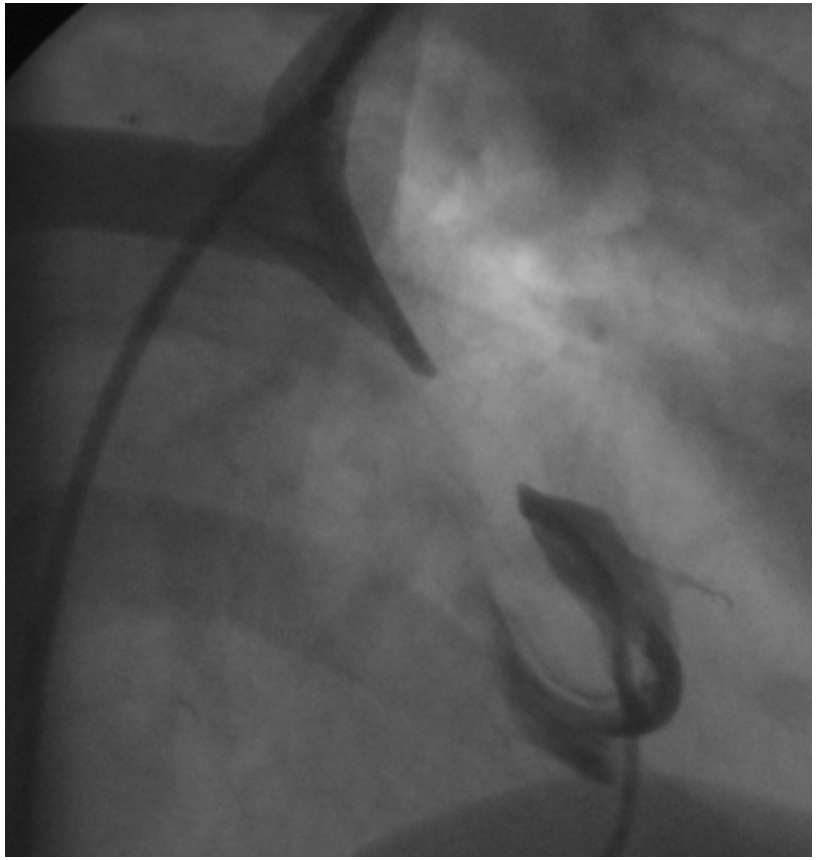

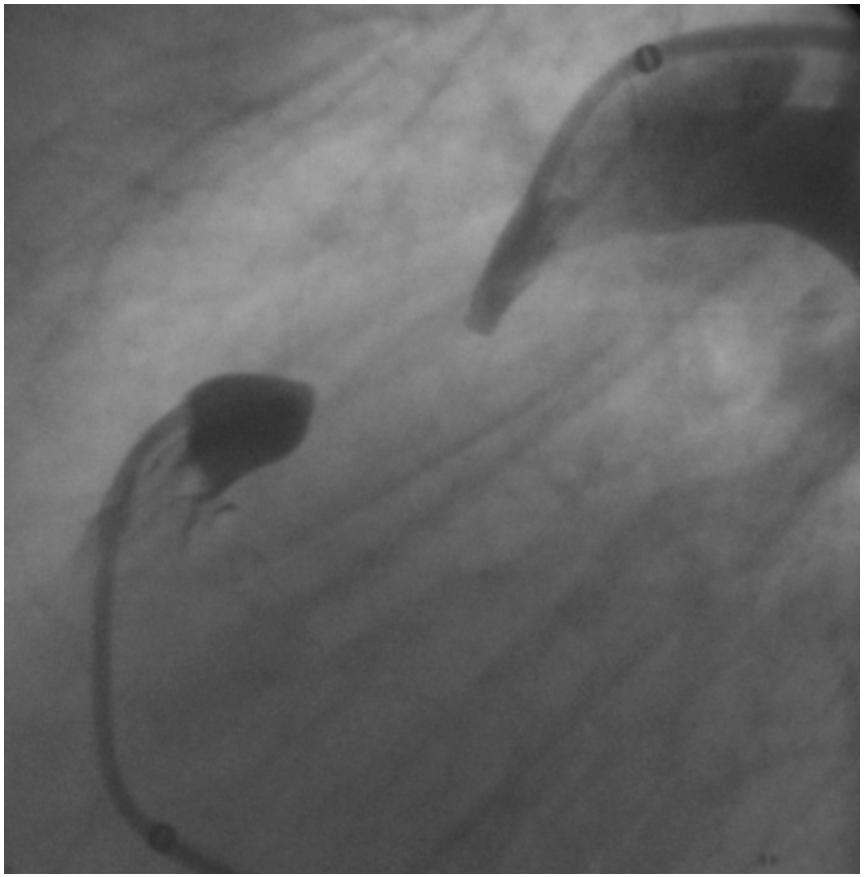

Langstreckige Atresie

Pulmonalatresie mit VSD

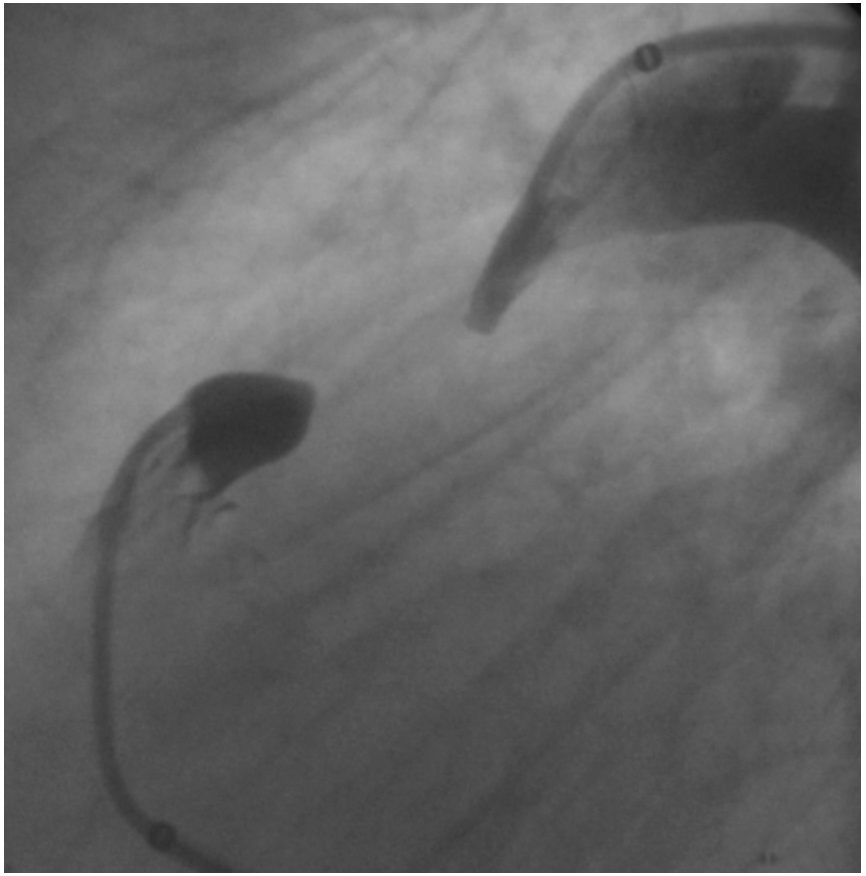

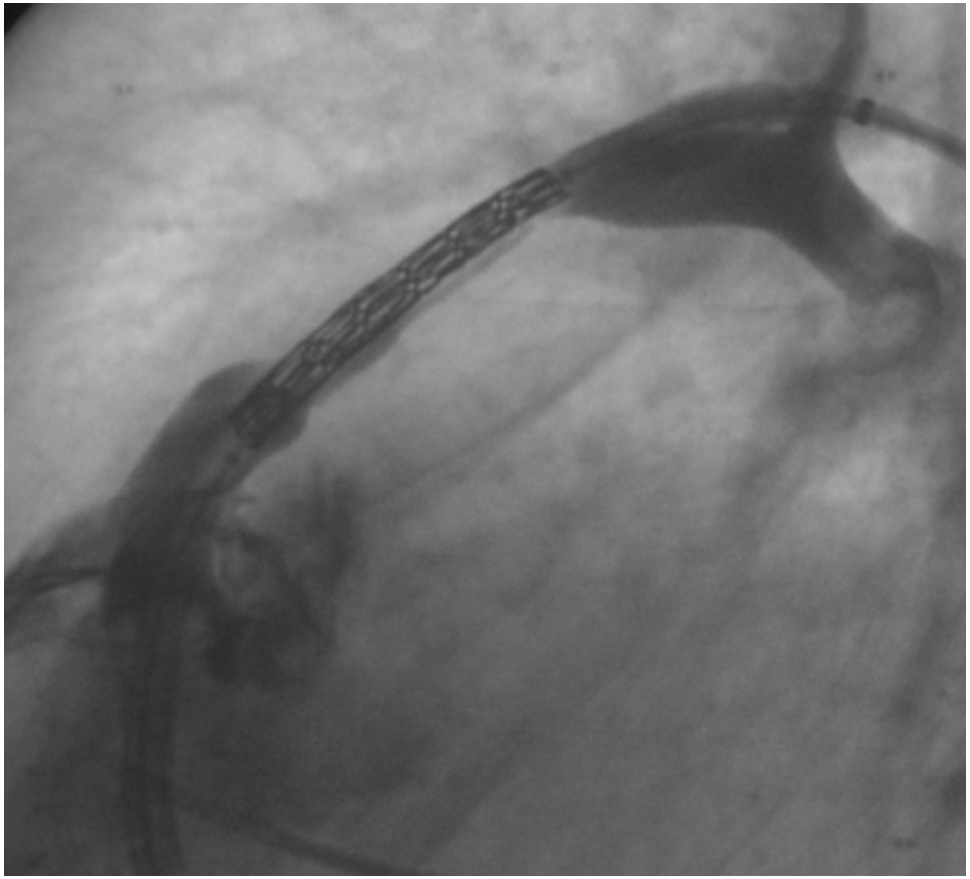

Implantation eines gecoverten Stents

Pulmonalatresie mit VSD

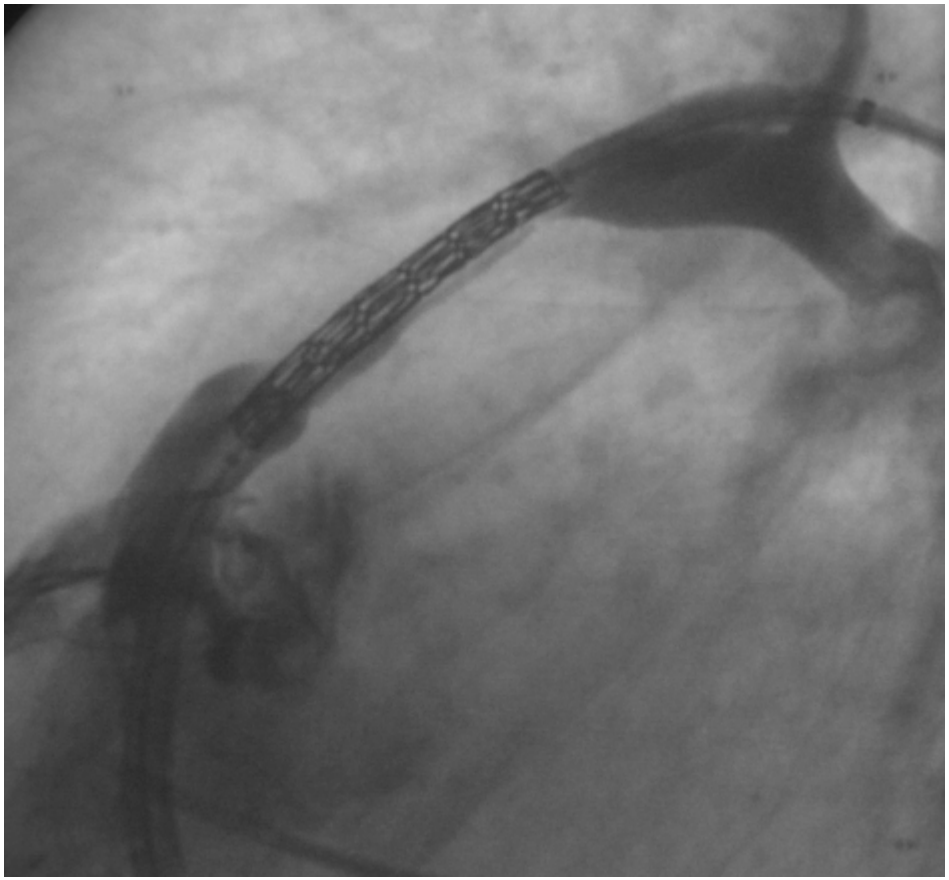

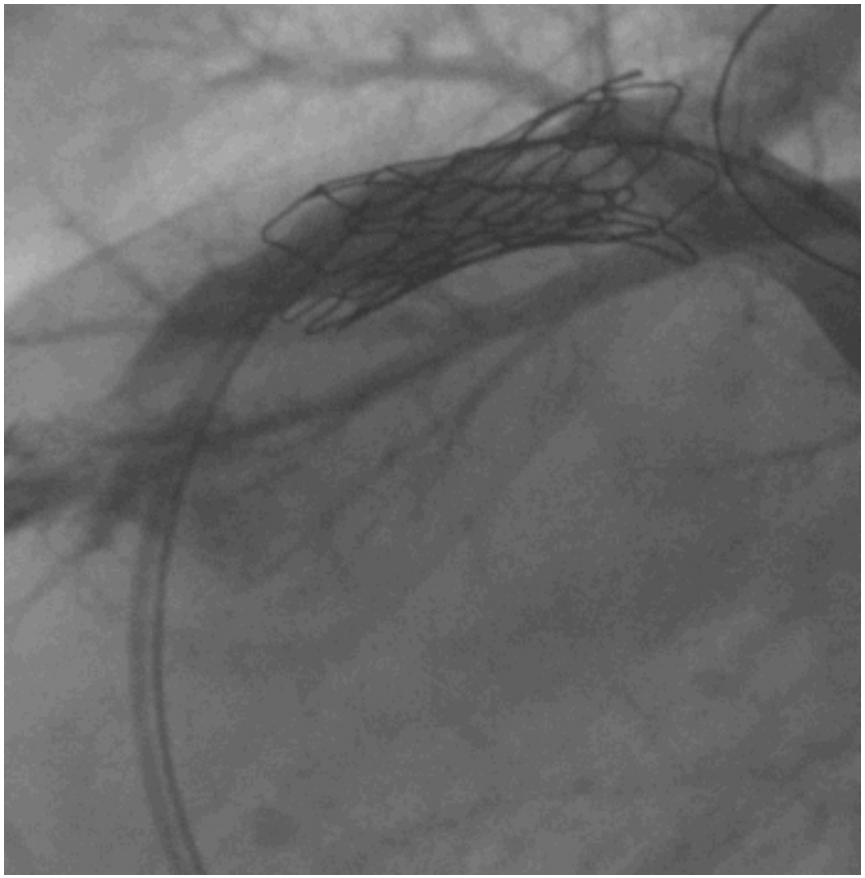

Implantation eines gecoverten Stents

Katheterinterventioneller Shunt

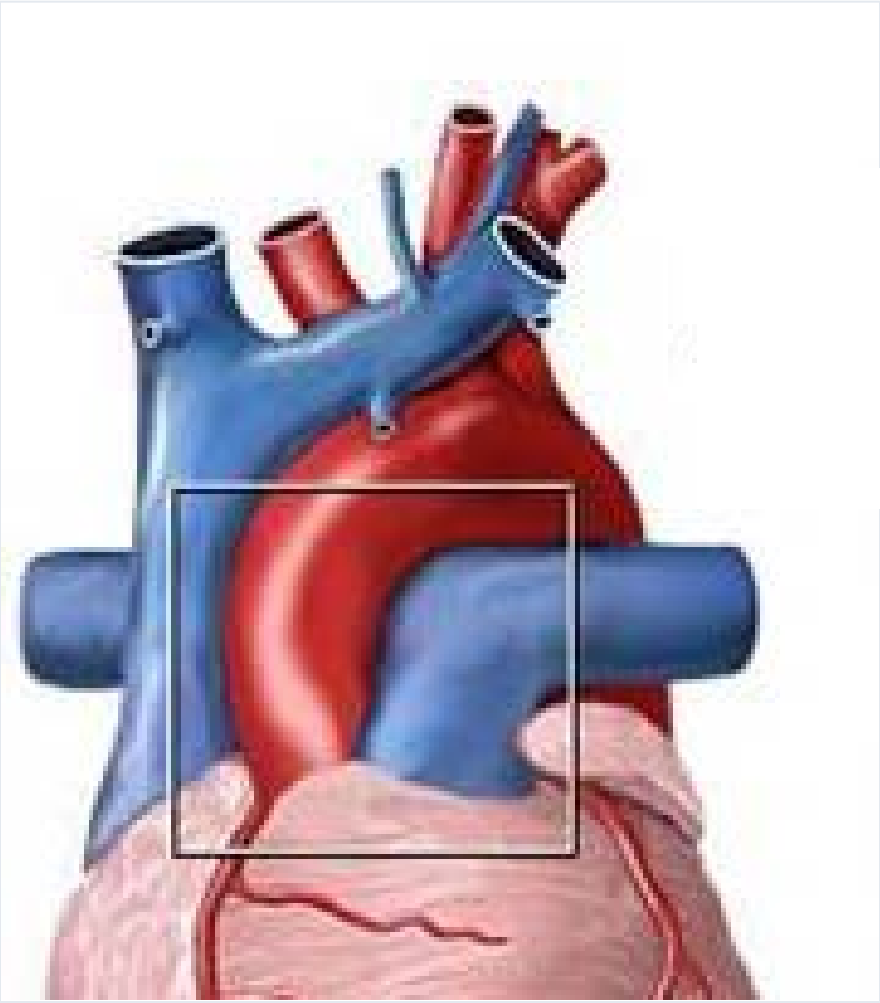

Nachbarschaft von Aorta und Pulmonlarterie

Katheterinterventioneller Shunt

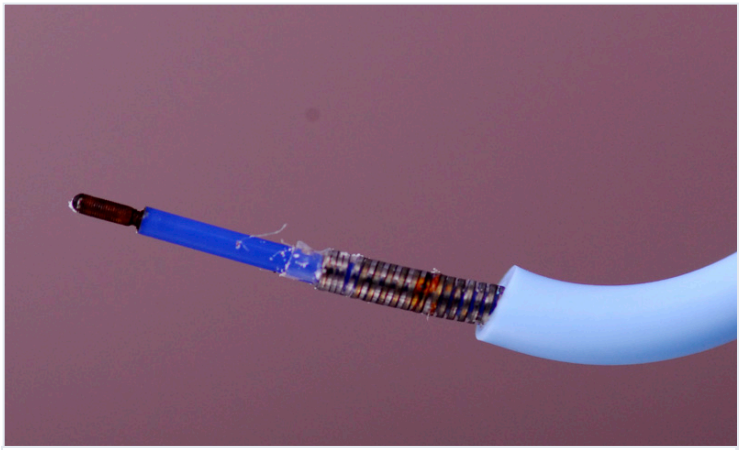

radio frequency perforation generator and catheter

+

premounted covered stent in appropriate size

Katheterinterventioneller Shunt

Simultaneous
PA and Ao angiography

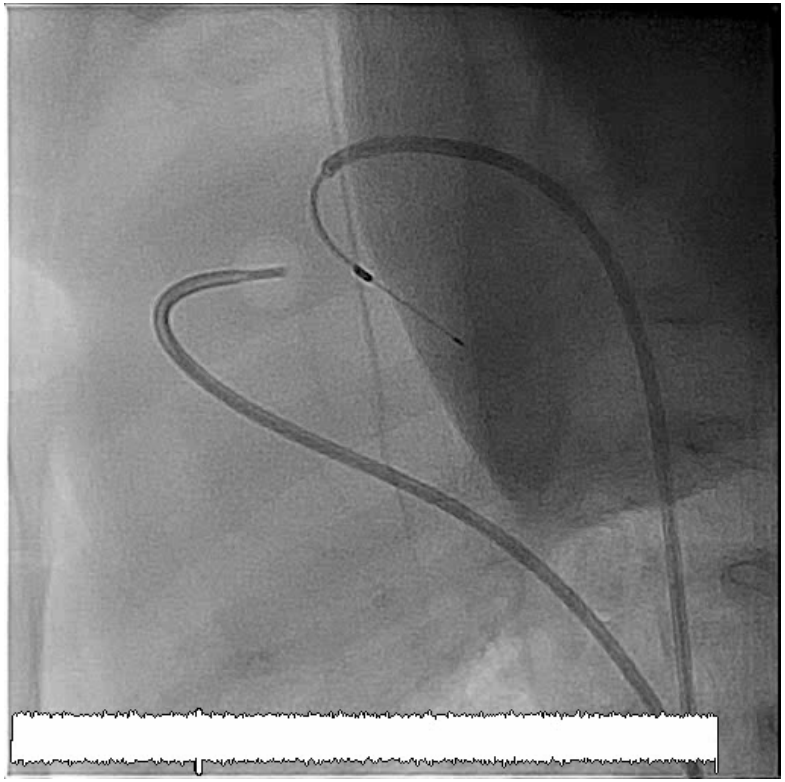

Perforation from Ao into PA

Katheterinterventioneller Shunt

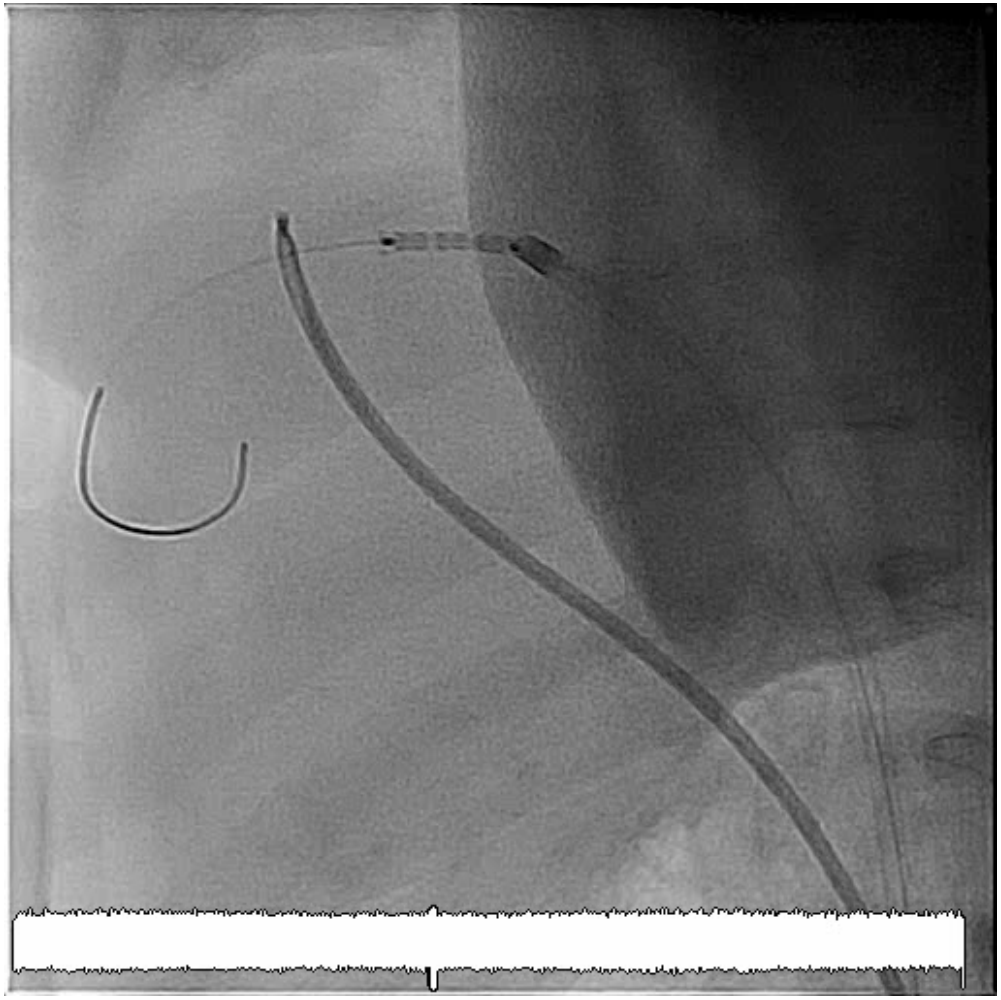

Stent implantation through 5F sheath

Katheterinterventioneller Shunt

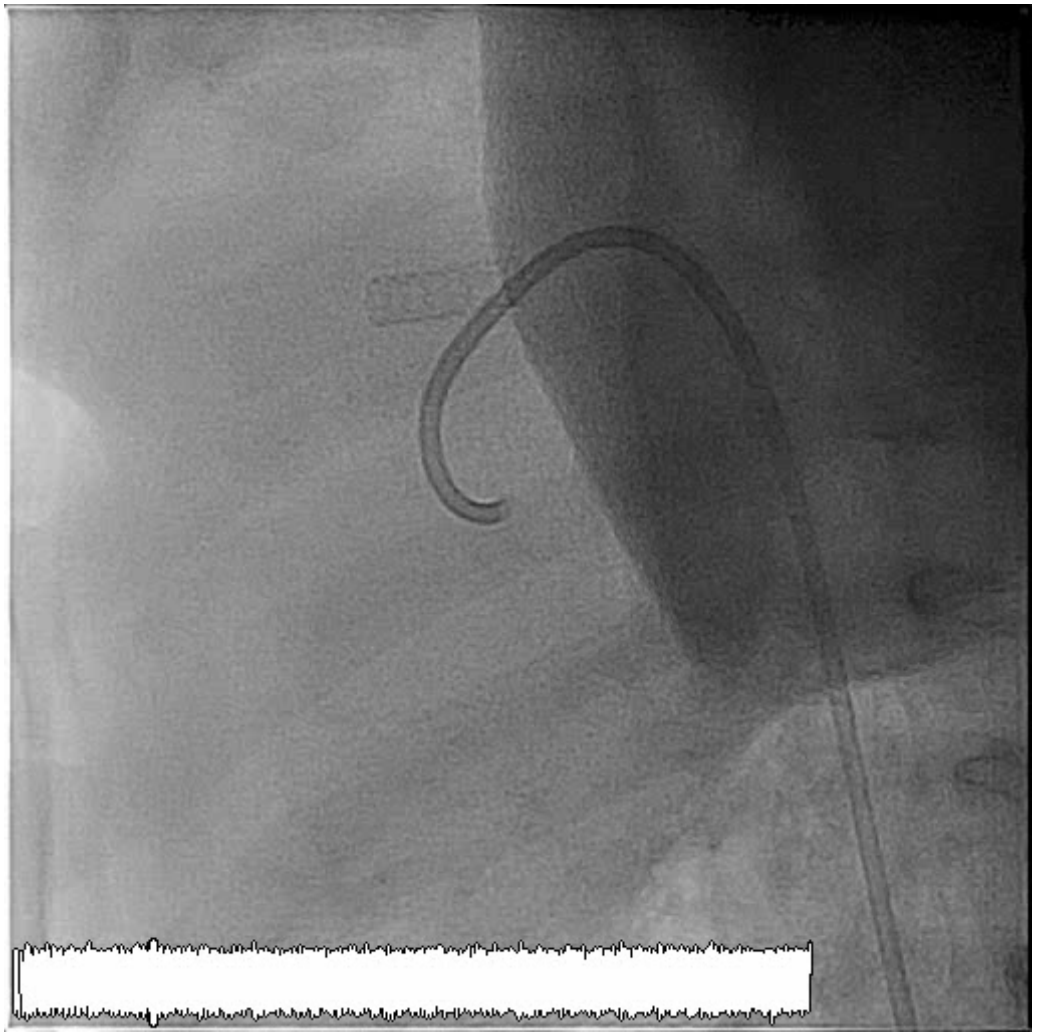

Qp:Qs 2.4 : 1

Katheterinterventioneller Shunt

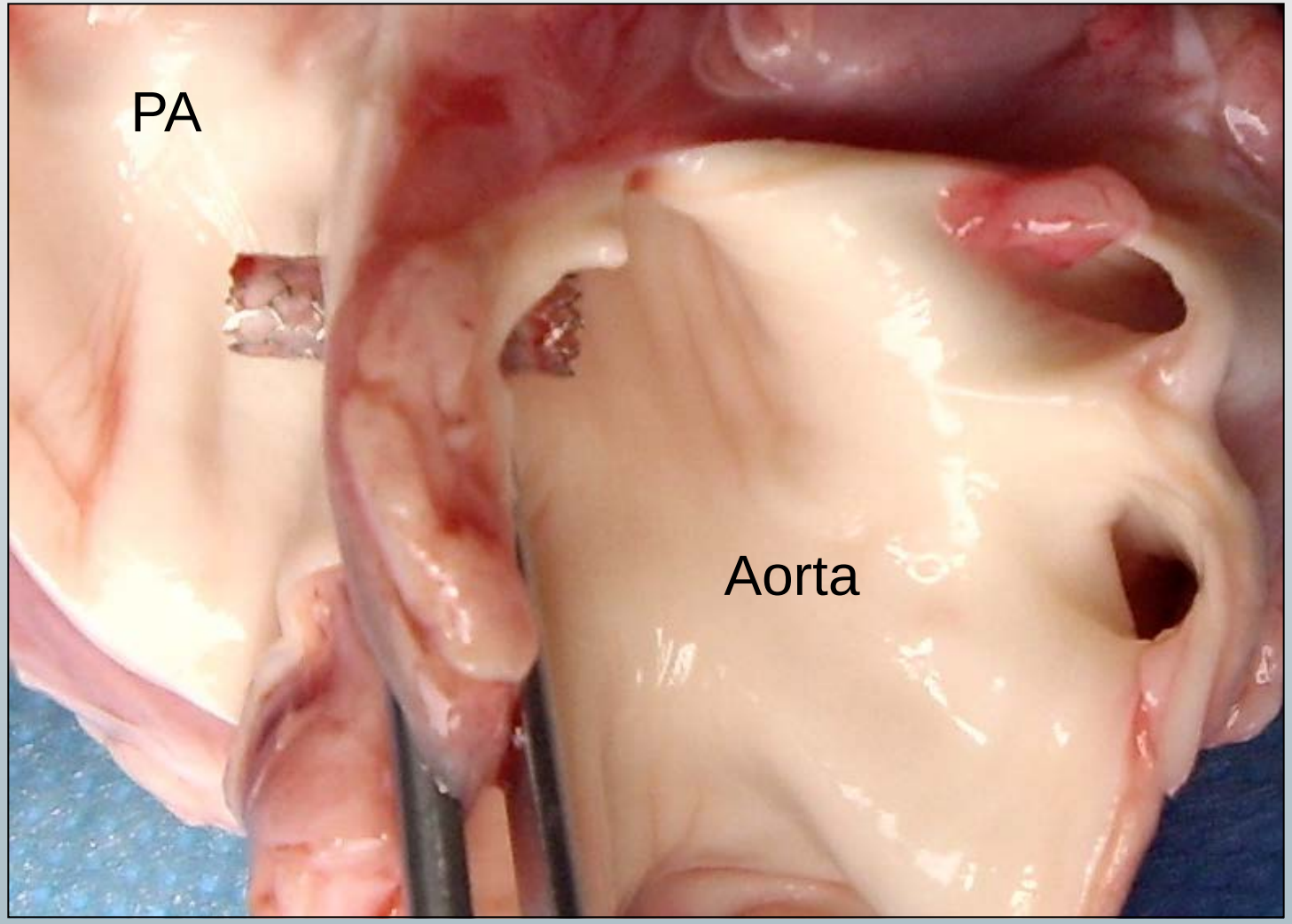

Gecoverter Stent zwischen Aorta und Pulmonalarterie

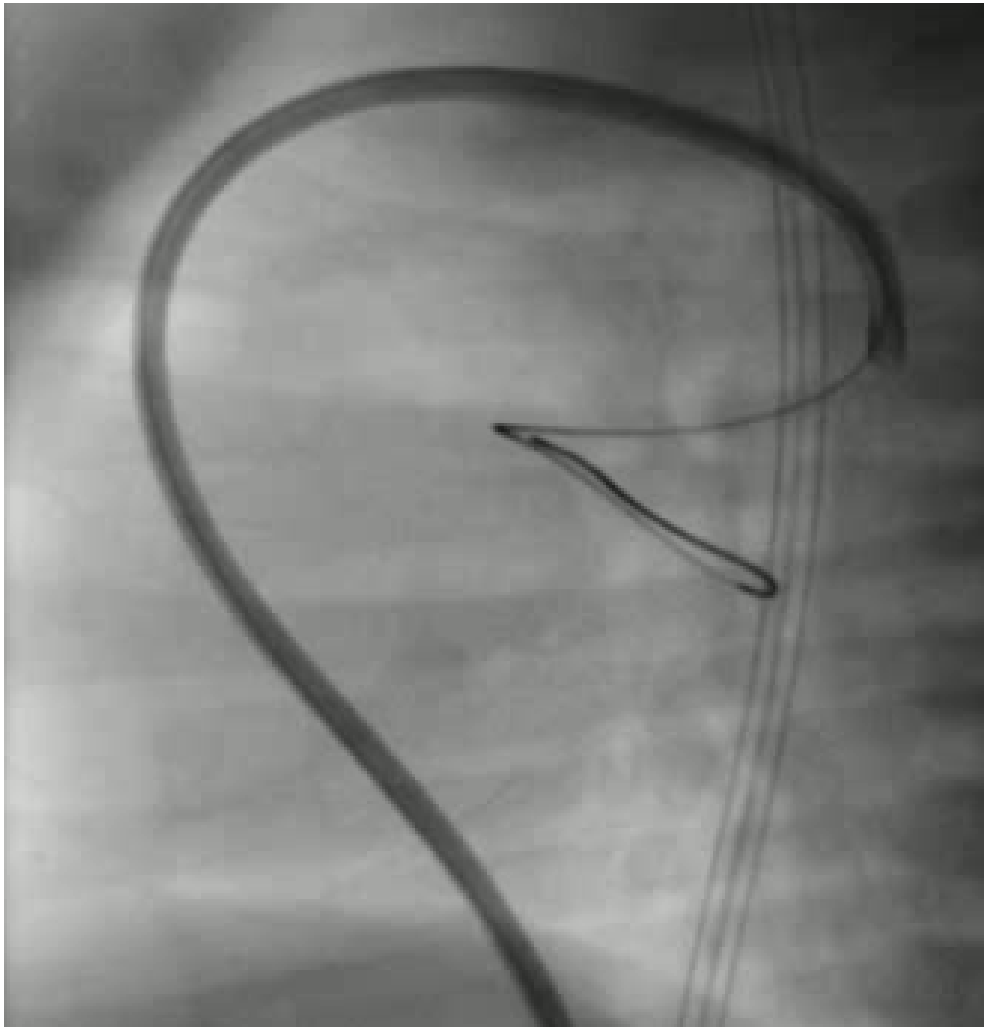

Ductus-Stent

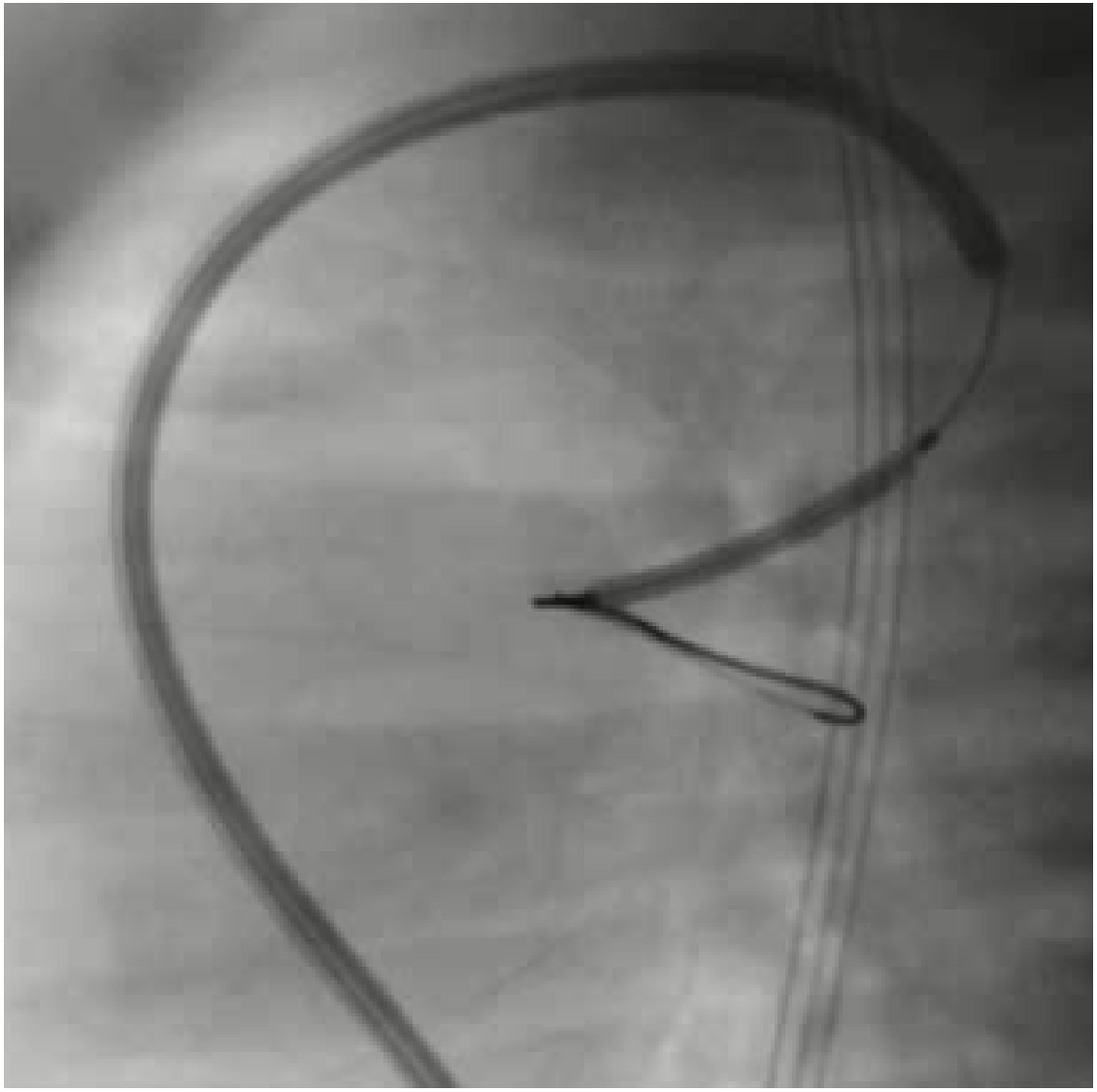

Ductus-Stent

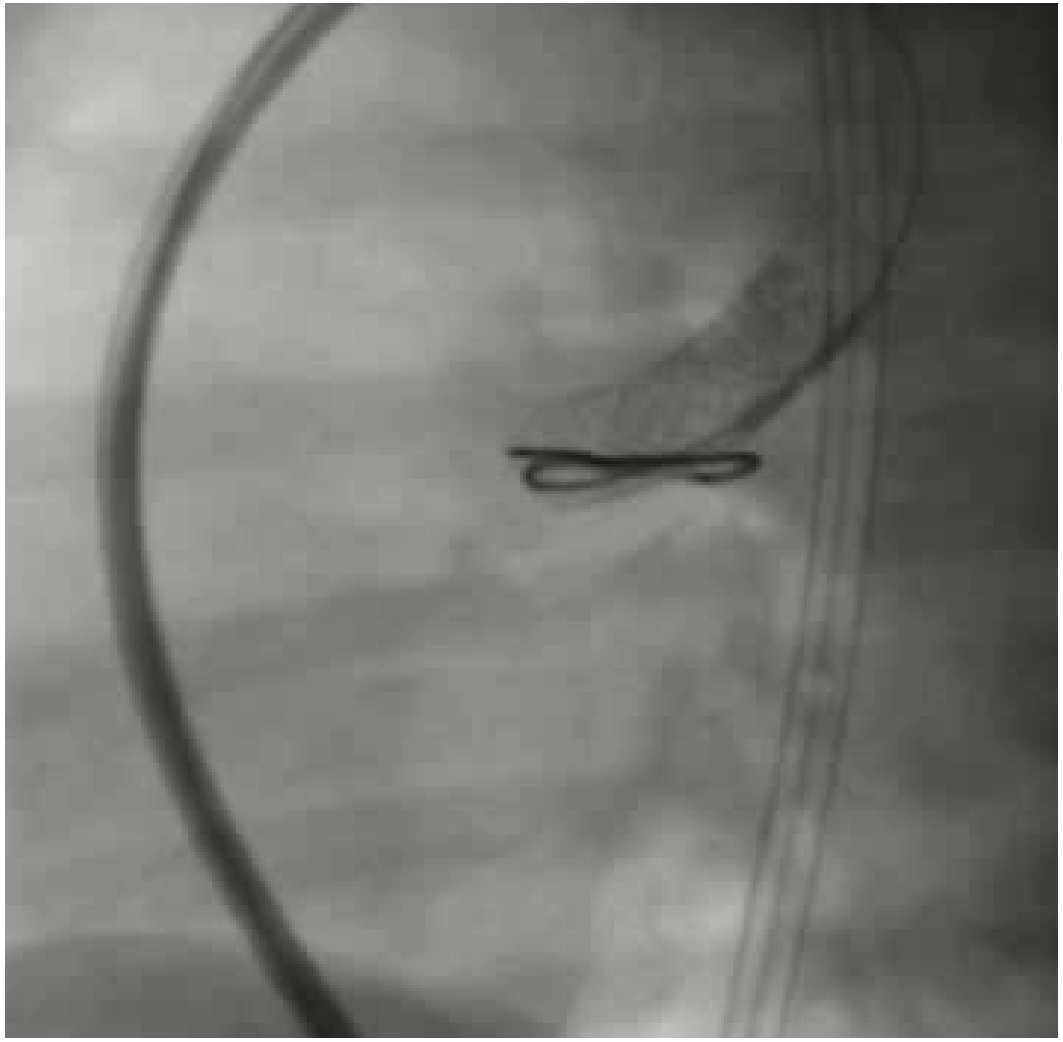

Ductus-Stent

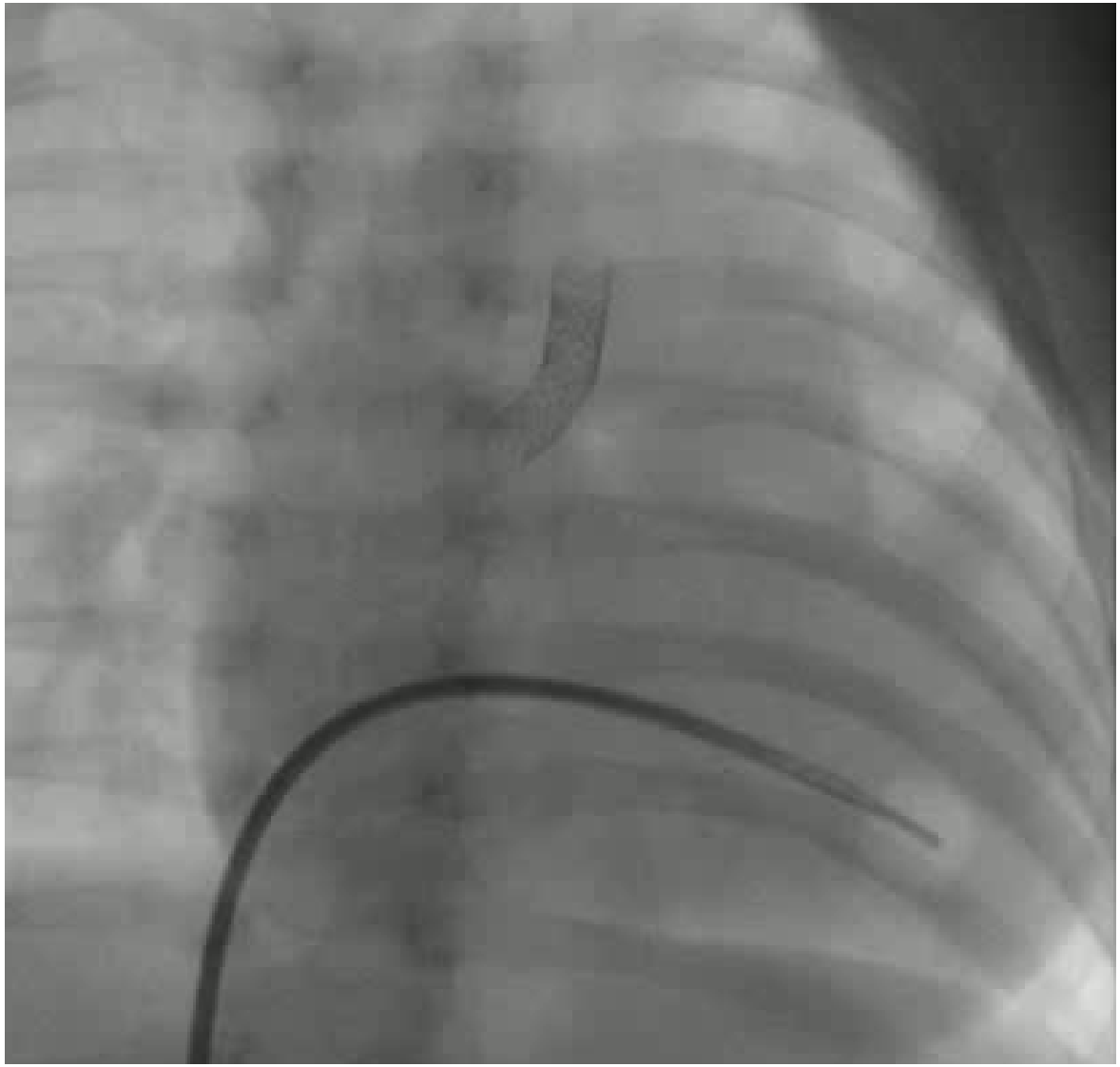

Ductus-Stent
nach drei Monaten

Ductus-Stent
nach drei Monaten

ANIFS, Augsburg 2020

Stent im rechtsventrikulären Ausflußtrakt

Stent im rechtsventrikulären Ausflußtrakt

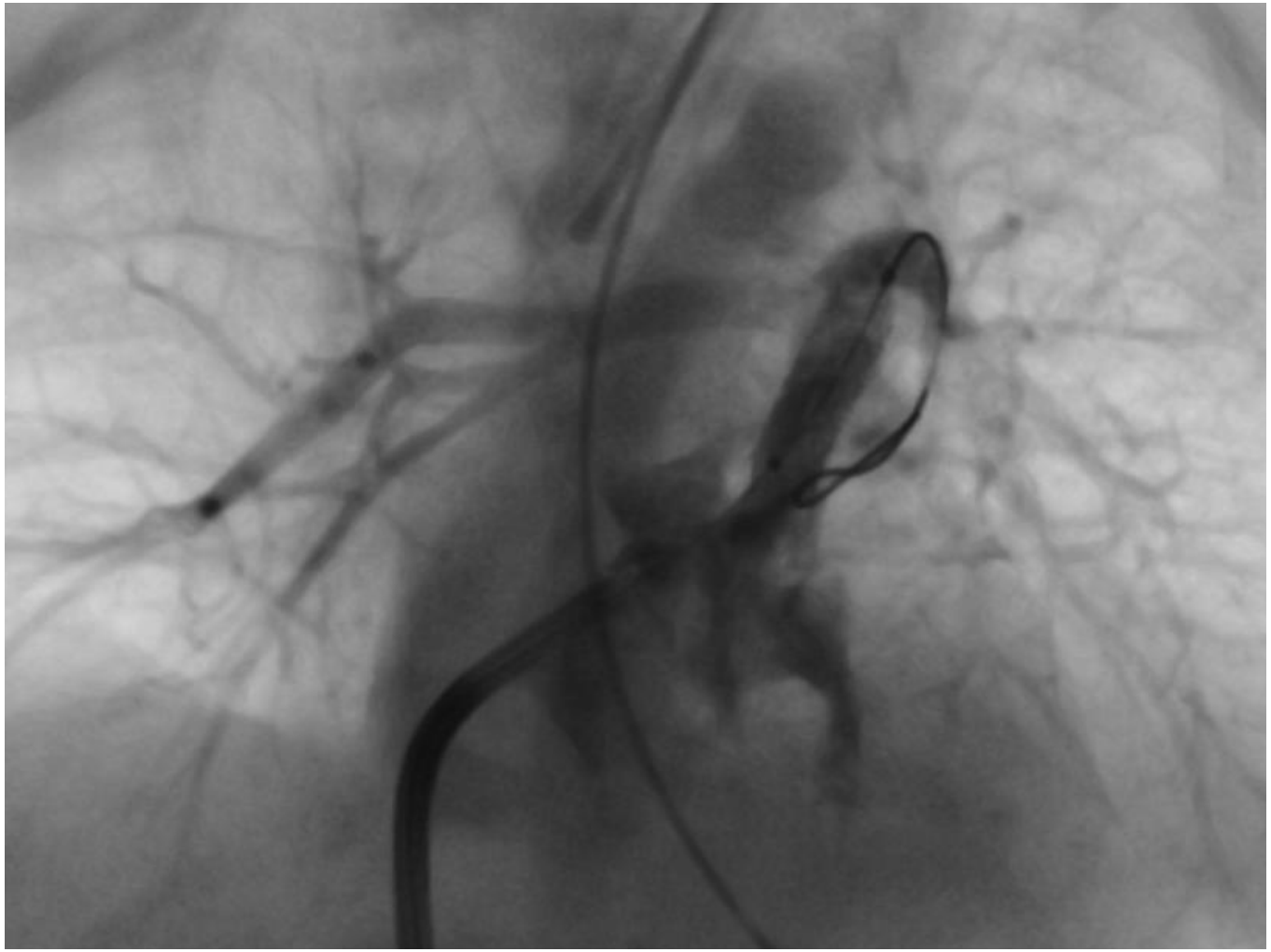

Stent im rechtsventrikulären Ausflußtrakt

Pulmonalatresie ohne VSD

(=hypoplastisches Rechtsherz)

Pulmonalatresie ohne VSD

(=hypoplastisches Rechtsherz)

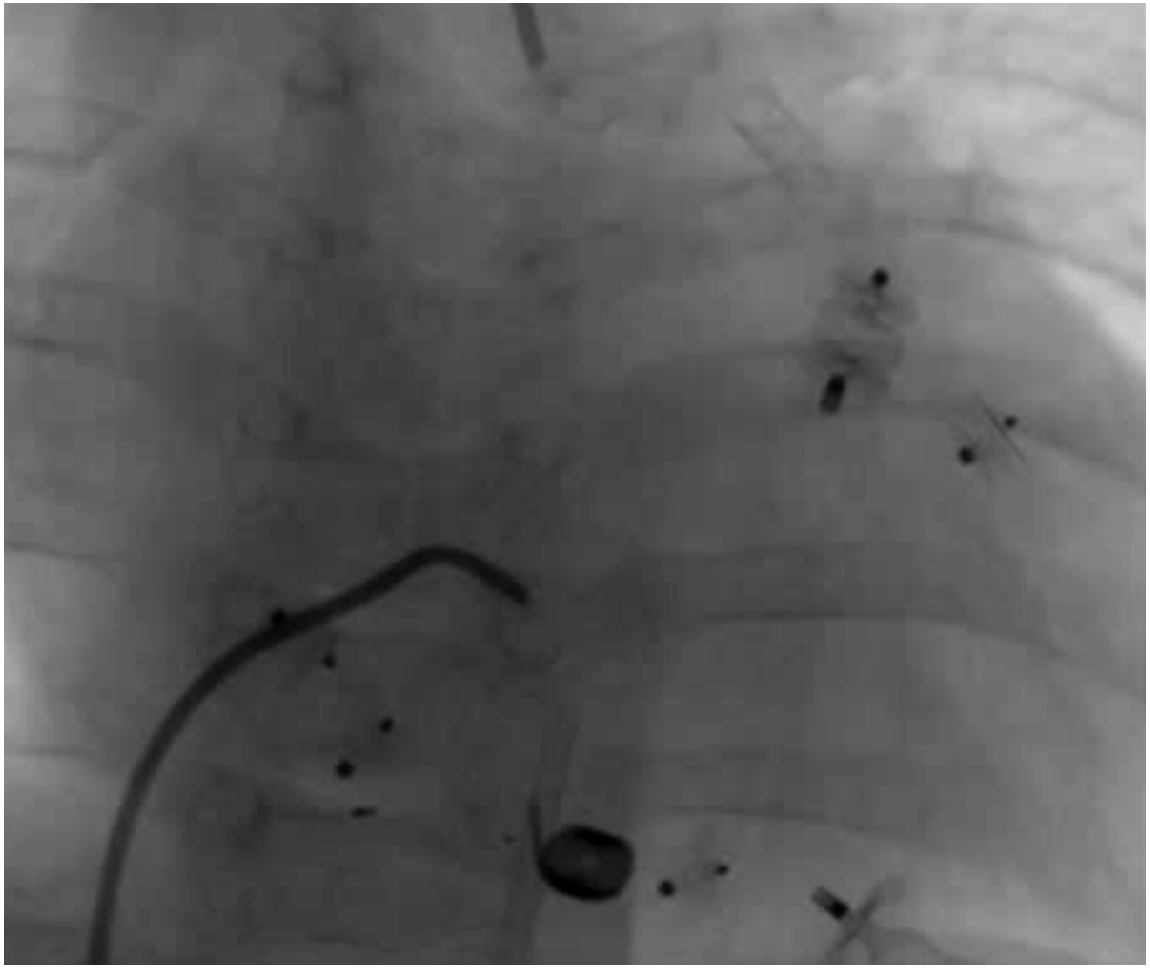

Pulmonalatresie ohne VSD

(=hypoplastisches Rechtsherz)

Ductus-Verschluß

Verschlüsse von 1990 – 6/2004
(=hypoplastisches Rechtsherz)

776

OP und IV

439pts. > 1Yr

1 OP vs. 438 IV

337pts. < 1Yr

305 OP vs. 32 IV

Ductus-Verschluß

FG 2,2 kg, 4F venös, AVP IV, 6,5min. DI-Zeit

Wo stehen wir?

Trends in Patent Ductus Arteriosus Diagnosis and Management for Very Low Birth Weight Infants

Samantha Ngo, BA,[a] Jochen Profit, MD, MPH,[b,c] Jeffrey B. Gould, MD, MPH,[b,c] Henry C. Lee, MD, MS[b,c]

PEDIATRICS Volume 139, number 4, April 2017:e20162390

134
Krankenhäuser
2008-2014
>28 000 ELBW

FIGURE 3

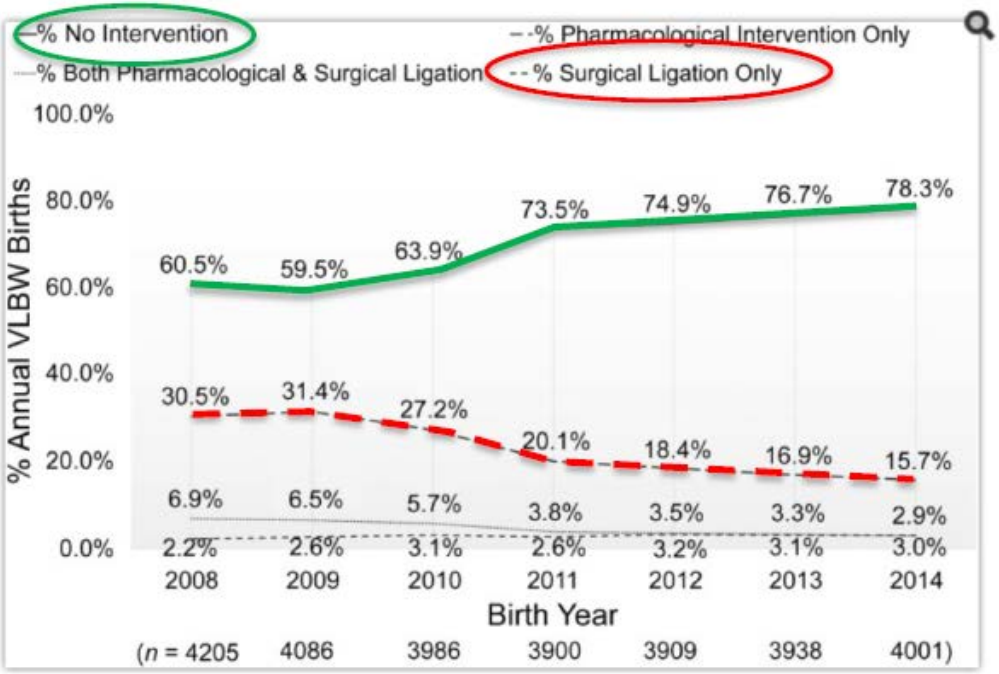

Hospital management of PDA in VLBW infants weighing <1500 g across 134 California hospitals, stratified by treatment intervention level, 2008 to 2014 (*N* = 28 025).

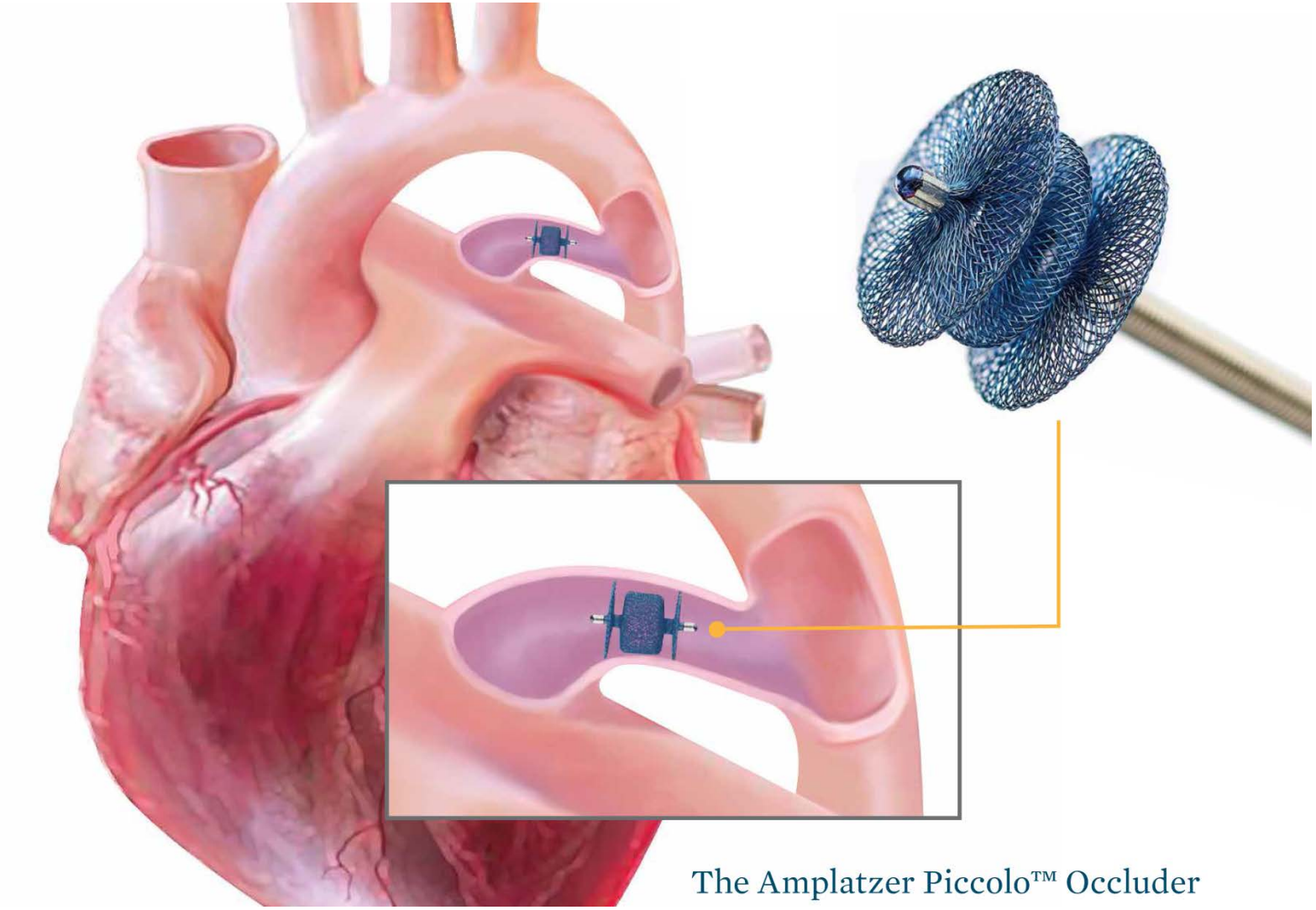
The Amplatzer Piccolo™ Occluder

PDA in FG - Devices

70%

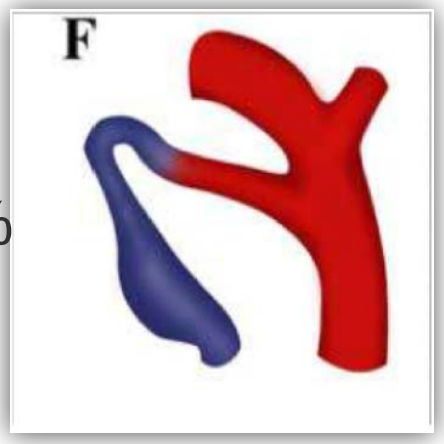

16%



ADO II AS = Piccolo

Model/Reorder Number	Waist Diameter (mm) [A]	Length Between Retention Discs (mm) [B]	Disc Diameter (mm) [C]	Recommended Sheath Size[a]
9-PDA2AS-03-02-L	3	2	4.00	4 F, 90° Curve
9-PDA2AS-03-04-L	3	4	4.00	4 F, 90° Curve
9-PDA2AS-03-06-L	3	6	4.00	4 F, 90° Curve
9-PDA2AS-04-02-L	4	2	5.25	4 F, 90° Curve
9-PDA2AS-04-04-L	4	4	5.25	4 F, 90° Curve
9-PDA2AS-04-06-L	4	6	5.25	4 F, 90° Curve
9-PDA2AS-05-02-L	5	2	6.50	4 F, 90° Curve
9-PDA2AS-05-04-L	5	4	6.50	4 F, 90° Curve
9-PDA2AS-05-06-L	5	6	6.50	4 F, 90° Curve

a. AMPLATZER™ TorqVue™ LP Catheter is recommended for use with the AMPLATZER Duct Occluder II Additional Sizes.

PDA Verschluss bei FG

potentielle Probleme

- Femoralarterie
- geeignetes Device
- LPA und AoD Obstruktion
- Embolisation
- Transport
- Strahlung
- ……

Piccolo Trial

- 100 Patienten in 8 Zentren in USA

Variable	Median	Range
Gestational age birth (weeks)	25.0	22-34
Weight at birth (gm)	720	430-1,495
Age implant (days)	36.5	10-97
Weight at implant (gm)	1,200	700-2,000

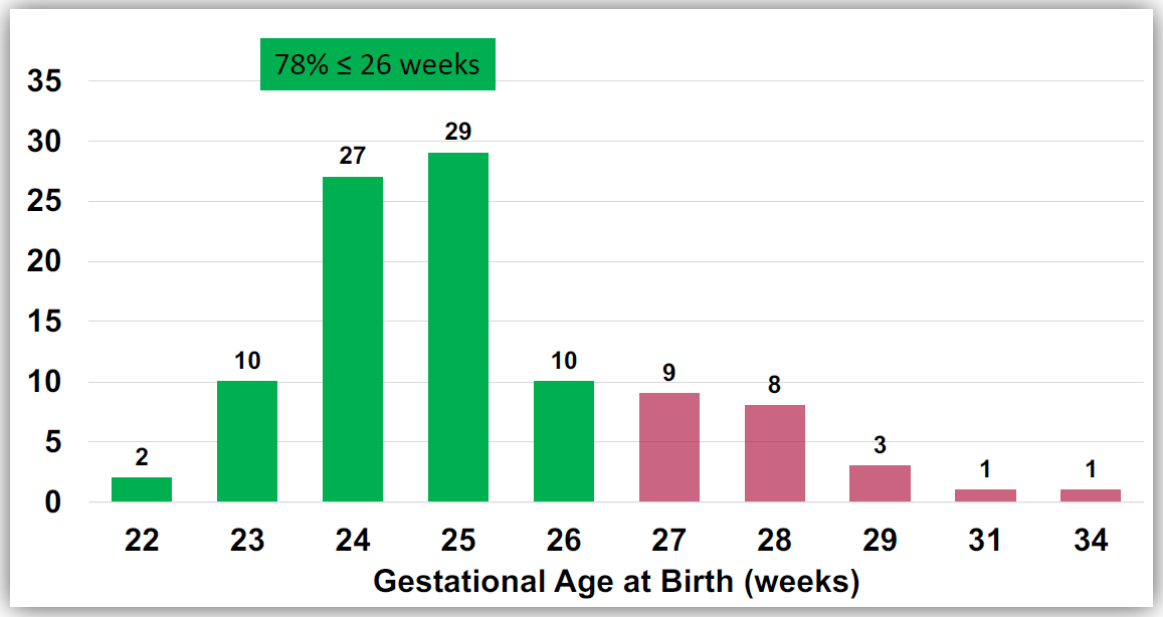

Zahn et al. 2019

Piccolo Trail - Prozedur

Successful Implant	**99/100 (99%)**
Intra-Procedural Embolization*	2/100 (2%)
Post-Procedural Migration**	1/100 (1%)

Zahn et al. 2019

Piccolo Trail - Prozedur

Variable	Median	Range
Procedure time (min)	38	14-230
Fluoroscopy time (min)	7.0	3-103
Contrast dose (cc/kg)	2.1	0-8.7

Zahn et al. 2019

Piccolo Trail - Komplikationen

Major bleeding (blood transfusion ≥ 20 cc/kg)	2/100
Hemolysis (history of congenital thrombocytopenia)	1/100
Non-serious vascular access complication	1/100
Significant tricuspid regurgitation	3/100
Coarctation Aorta	1/100
LPA Stenosis	0/100

Survival as of 2/15/19	(98/100) 98%

Zahn et al. 2019

Zugang für die Intervention

- Kein arterieller Zugang
- Punktion der v. femoralis mit Ultraschall, 4F Schleuse

FG 1400g

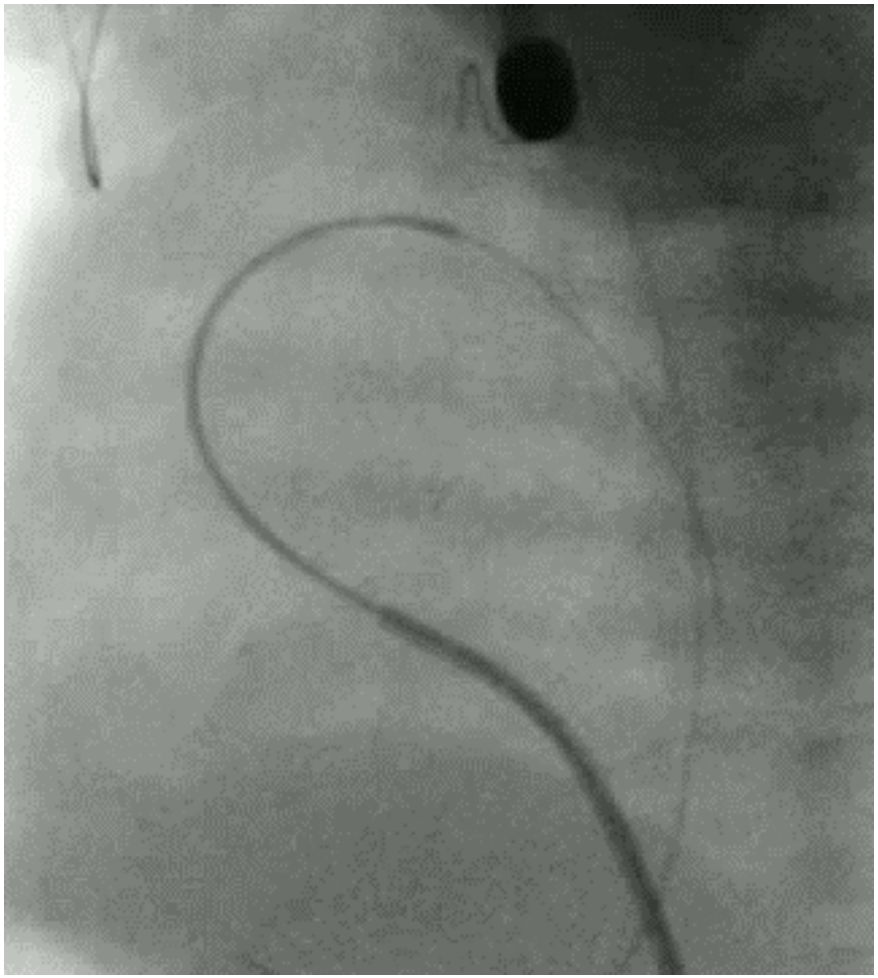

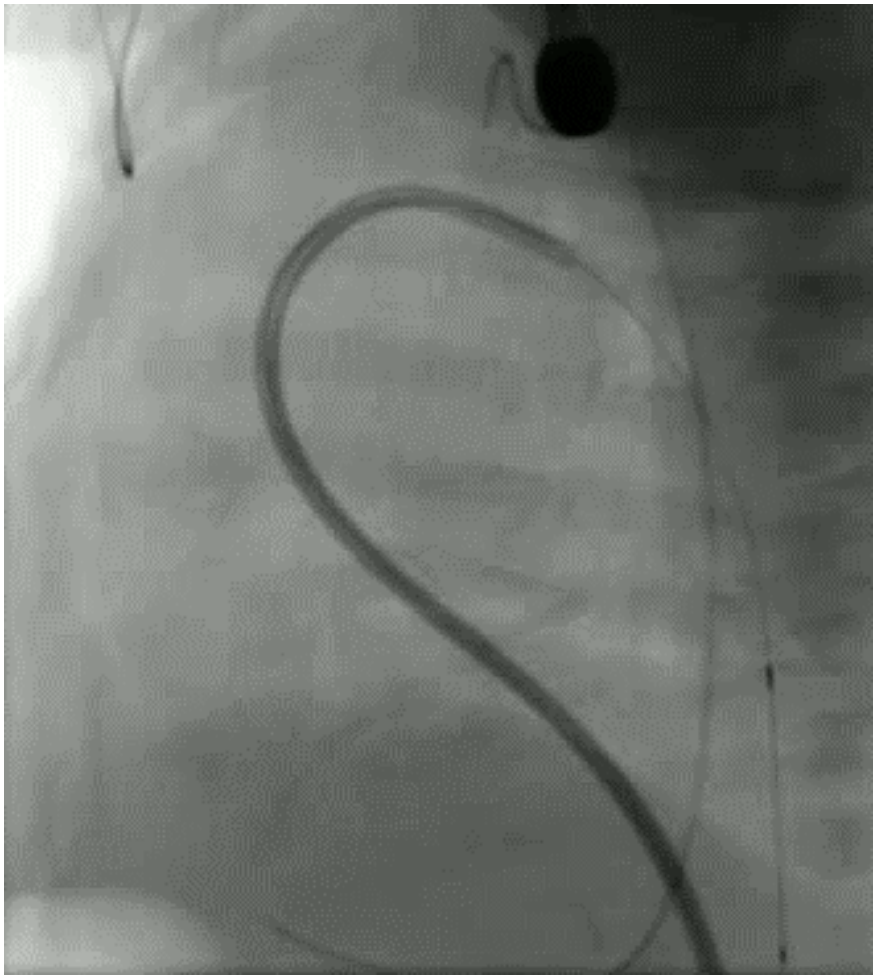

FG 1400g

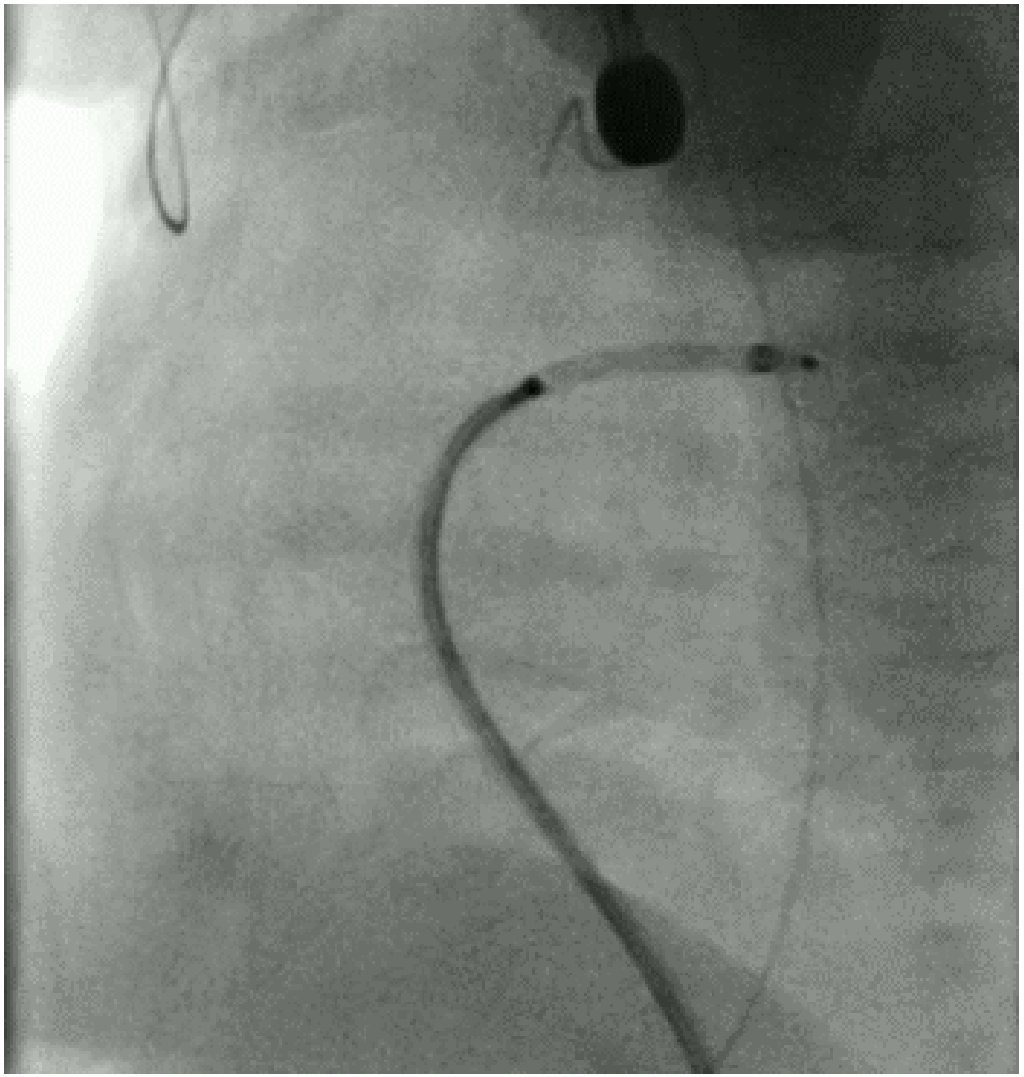

FG 1400g

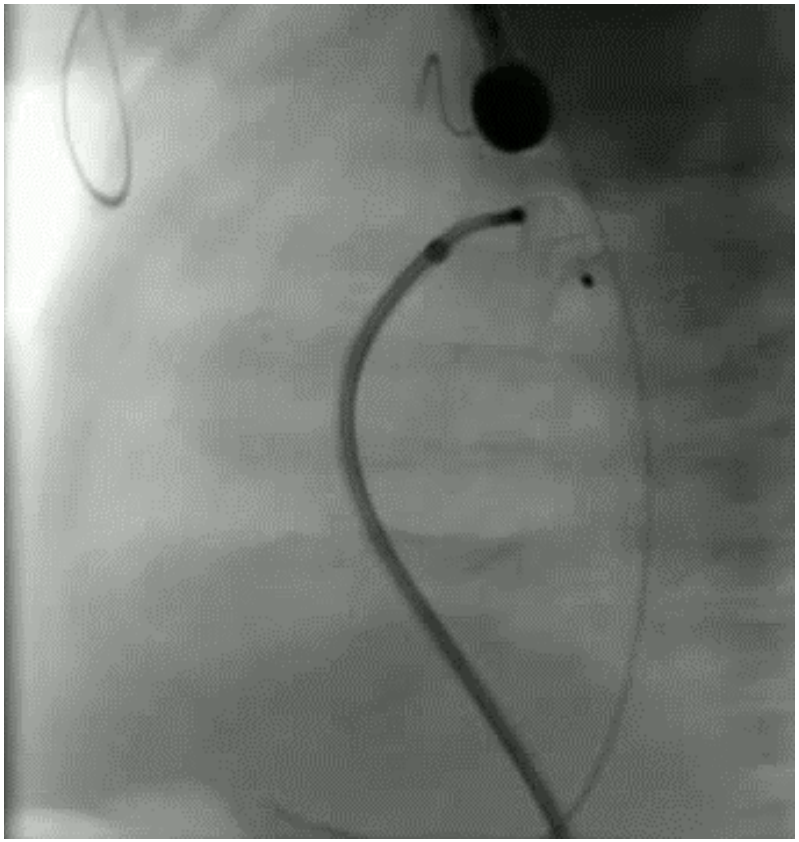

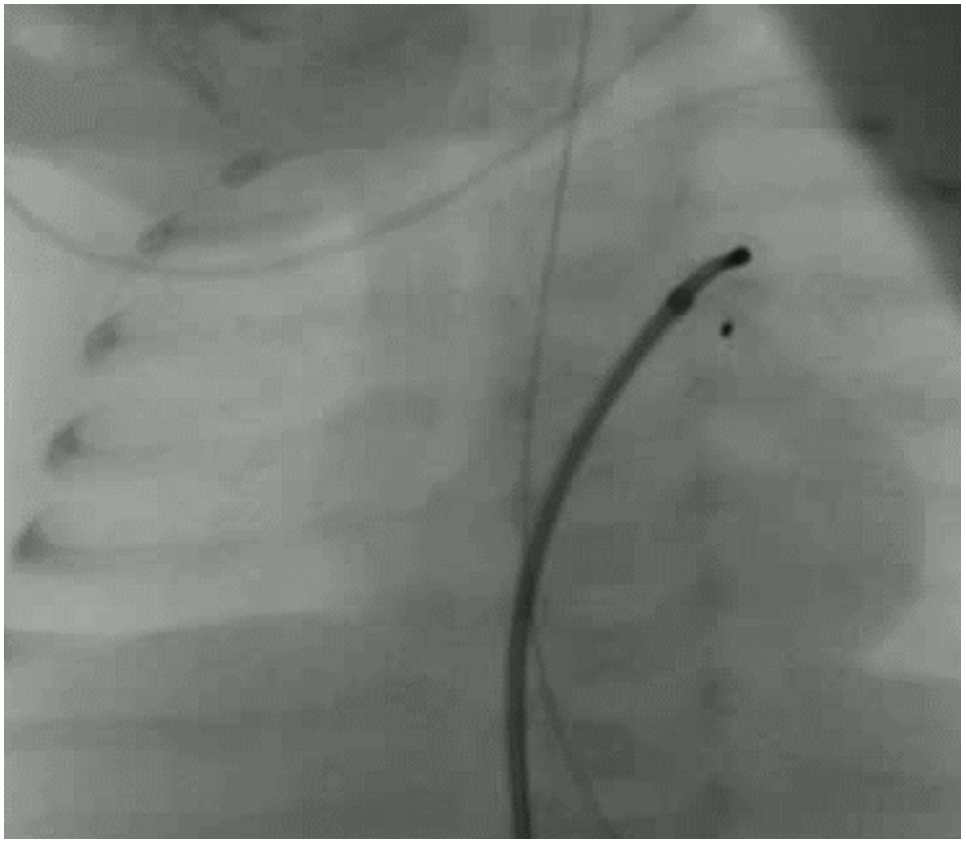

Nachteile

- Transport
- Strahlung

Unser Ziel

- PDA Verschluss am Inkubator mit Ultraschall



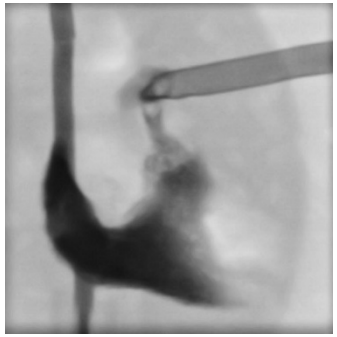

Interventioneller Ductusverschluß bei Frühgeborenen im Inkubator

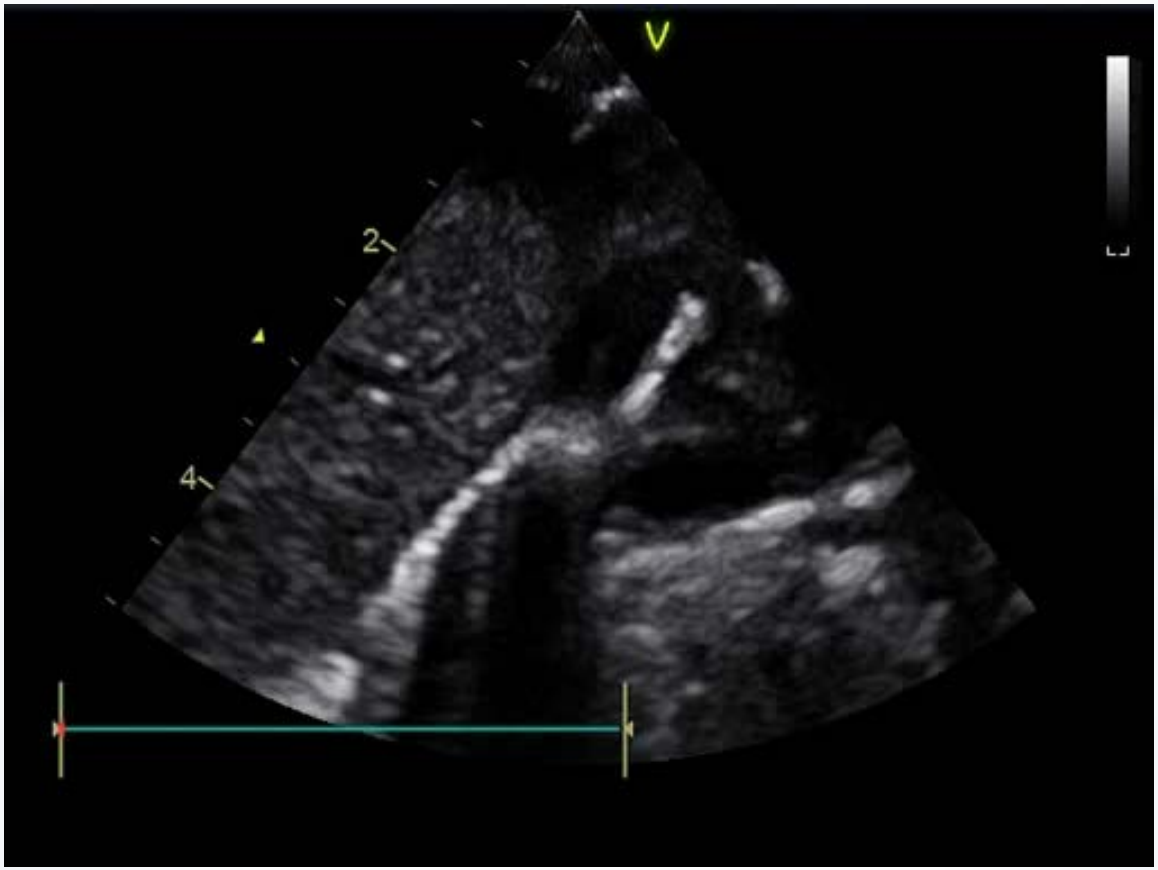

Interventioneller Ductusverschluß bei Frühgeborenen im Inkubator

Interventioneller Ductusverschluß bei Frühgeborenen im Inkubator

Interventioneller Ductusverschluß bei Frühgeborenen im Inkubator

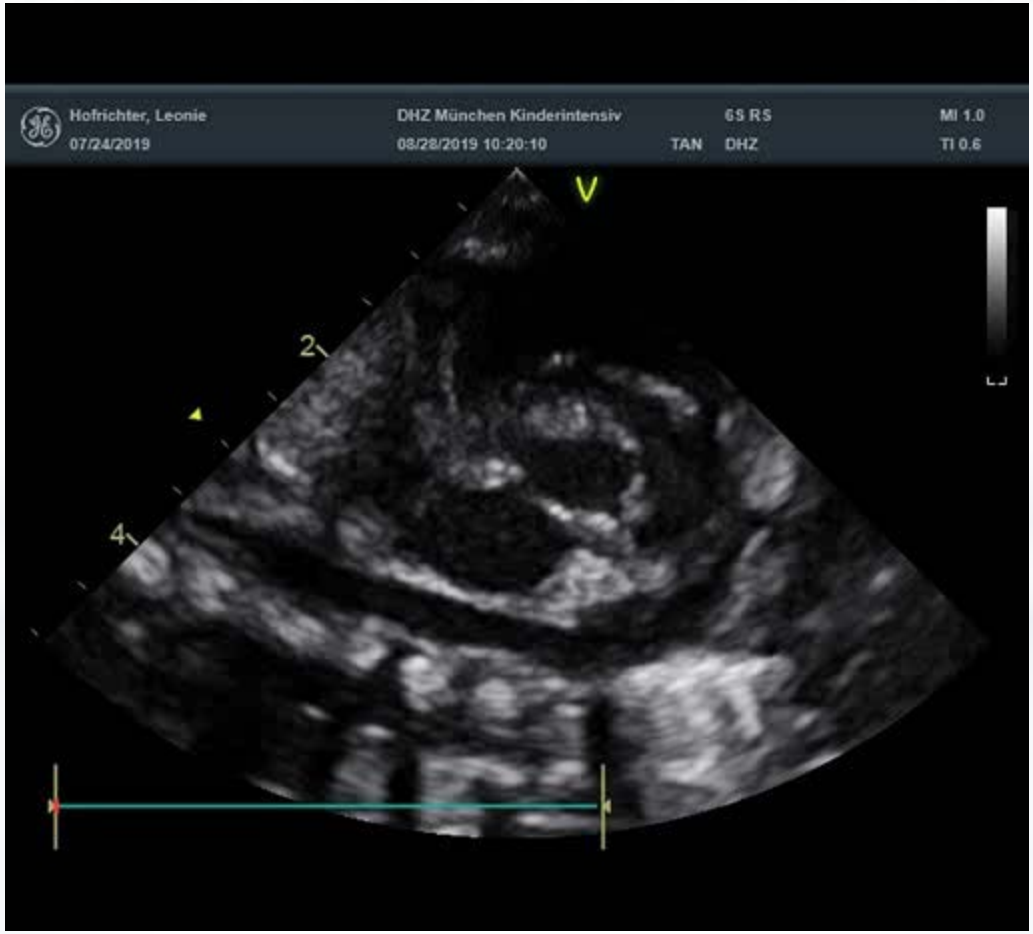

Interventioneller Ductusverschluß bei Frühgeborenen im Inkubator

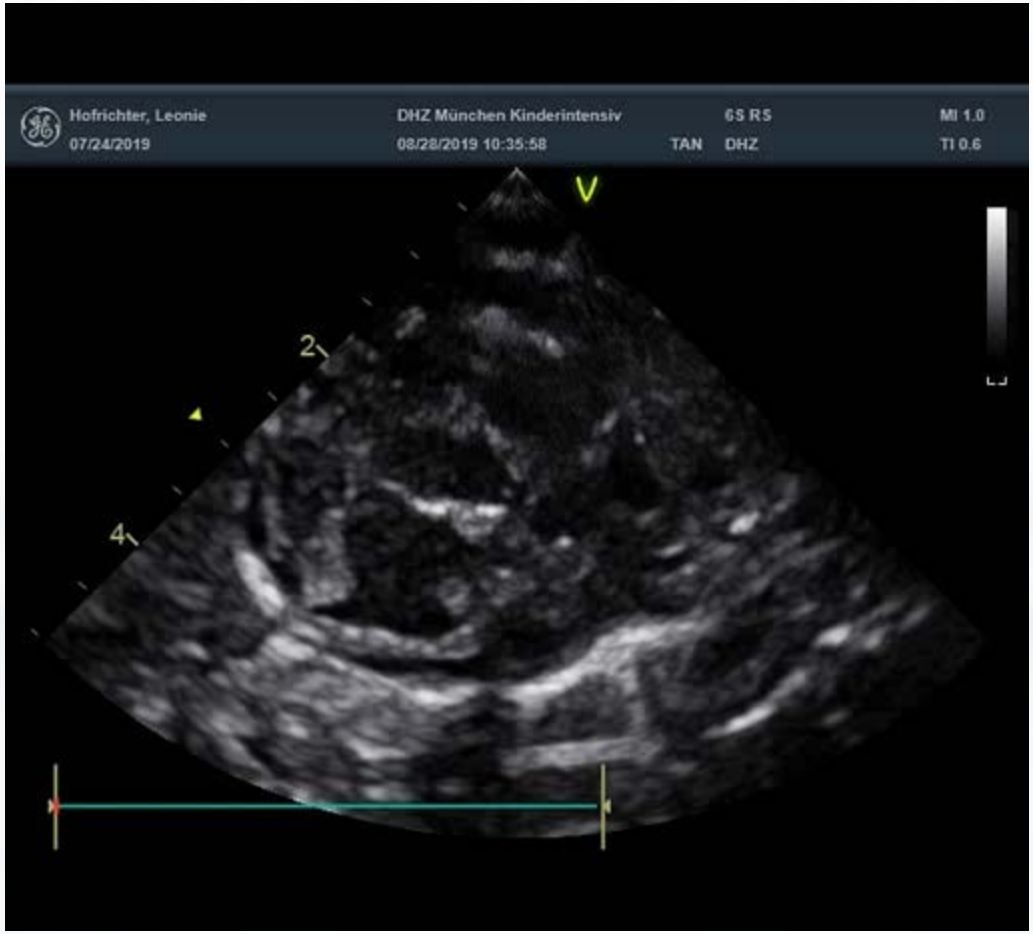

Interventioneller Ductusverschluß bei Frühgeborenen im Inkubator

Interventioneller Ductusverschluß bei Frühgeborenen im Inkubator

Interventioneller Ductusverschluß bei Frühgeborenen im Inkubator

Interventioneller Ductusverschluß bei Frühgeborenen im Inkubator

Interventioneller Ductusverschluß bei Frühgeborenen im Inkubator

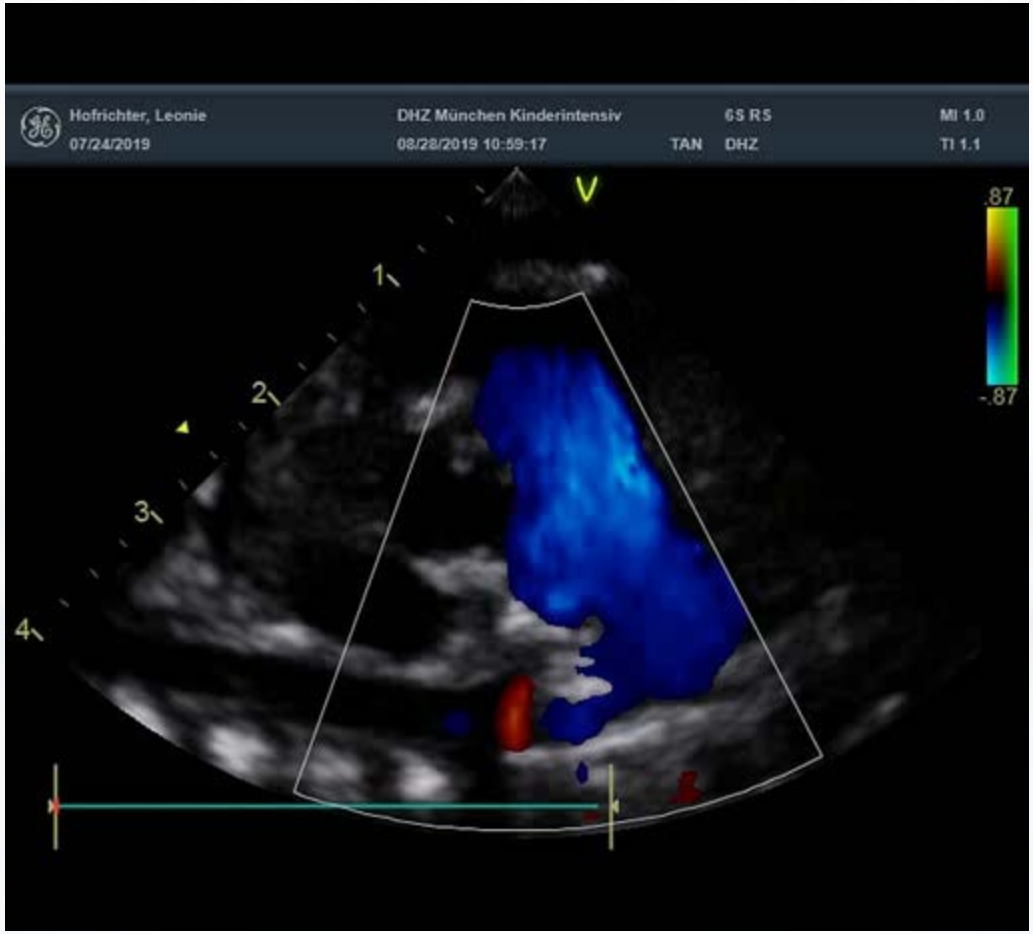

Interventioneller Ductusverschluß bei Frühgeborenen im Inkubator

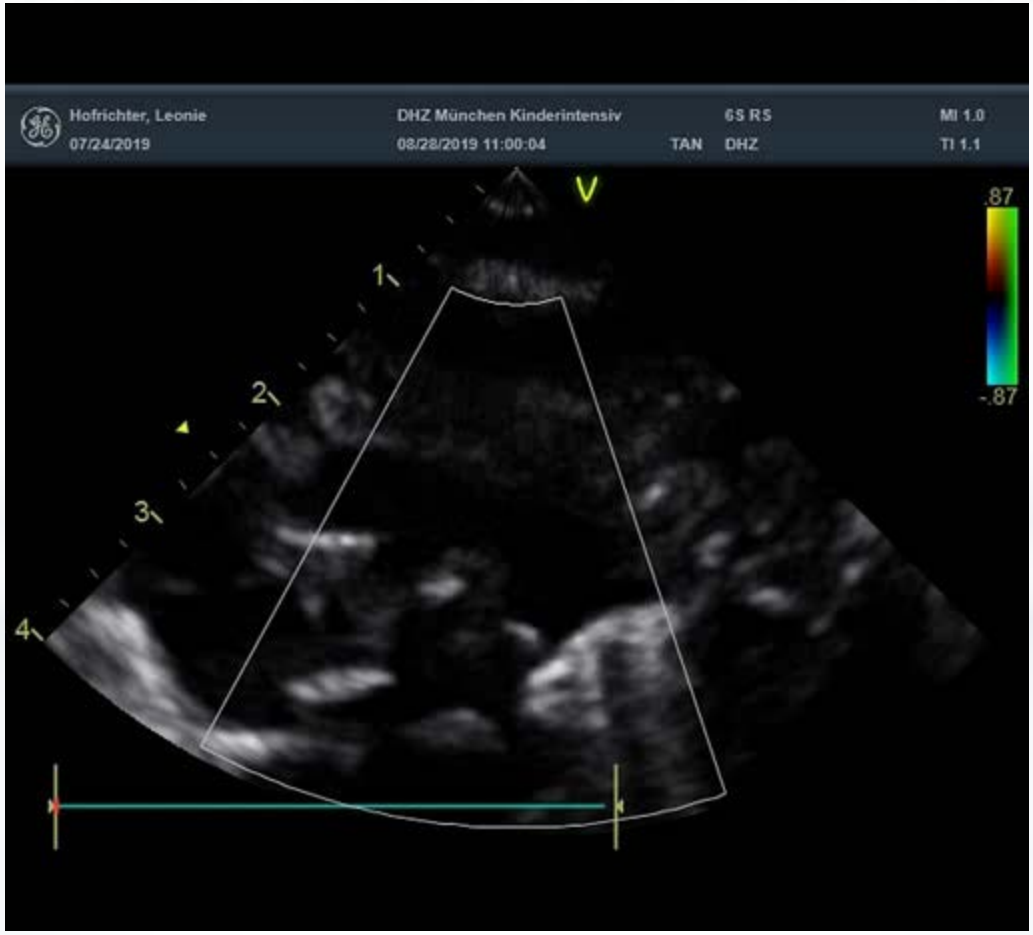

Interventioneller Ductusverschluß bei Frühgeborenen im Inkubator

PDA Verschluss bei FG

potentielle Probleme		Lösungen
• Femoralarterie	→	nur venöser Zugang
• geeignetes Device	→	Piccolo = ADO II AS
• LPA und AoD Obstruktion	→	Echo
• Embolisation	→	Bergung möglich
• Transport	→	Im Inkubator unter Echo Kontrolle
• Strahlung		
• ……	→	……

Interventioneller Ductusverschluß auf der neonatologischen Intensivstation

Dr. S. Georgiev

Dr. D. Tanase

ANIFS, Augsburg 2020

Herzkatheterinterventionen im Neugeborenen- und Säuglingsalter

Heutige Möglichkeiten und Perspektiven für morgen

P. Ewert
Deutsches Herzzentrum München

SAVE THE DATE
FIRST EUROPEAN PREMICLOSE
State of the art of the PDA closure in preterms
FRIDAY NOVEMBER 22nd 2019
Paris